

Disseminated *Nocardia farcinica* infection in a Patient with Pneumoconiosis

Soudabeh Aghajanpour^{1*}, Sara Abolghasemi¹, Hossein Dabiri², Shabnam Tehrani¹, Farshad Divsalar¹

¹ Infectious Diseases and Tropical Medicine Research Center, Shahid Beheshti University of Medical Sciences, Tehran, IR Iran

² Department of Clinical Microbiology, School of Medicine, Shahid Beheshti University of Medical Sciences, Tehran, IR Iran

*Corresponding author: Soudabeh Aghajanpour, Infectious Diseases and Tropical Medicine Research Center, Shahid Beheshti University of Medical Sciences, Tehran, IR Iran, E-mail: sou.aghajanpour@gmail.com, Tel: +982122439963

Submitted: July 23, 2017; Revised: September 04 2017; Accepted: September 05, 2017

Abstract

Background: *Nocardia* as a Gram-positive bacillus with a microscopic appearance of branching hyphae can produce considerable disease in an appropriate host. *N. farcinica* is a member of genus *Nocardia* that is potentially life threatening; therefore, therapy of *N. farcinica* infection remains difficult.

Case presentation: This study is a case report of disseminated *N. farcinica* infection in a 64-year-old man with a history of pneumoconiosis with brain, lung, and skin involvement in Labbafi Nejad hospital, Tehran, IR Iran in November 2013 with a discussion about diagnosis and management of this particular patient.

Conclusion: Due to the involvement of brain, triple therapy was started with meropenem, amikacin, and linezolid.

Key words: Pneumoconiosis, *Nocardia farcinica*, Brain abscess

1. Background

Nocardiosis is typically regarded as an opportunistic infection. Disseminated *Nocardia* has a dismal prognosis with high mortality rates (1). In this study, the treatment of disseminated nocardiosis with brain abscess is described in an immunocompetent old patient with pneumoconiosis by combining linezolid, meropenem, and amikacin. Pneumoconiosis is a pulmonary occupational disease caused by inhalation of soil often in dust and in farming (2).

A 64-year-old man with a history of working in brick factory for twenty years was admitted to the Labbafi Nejad hospital, Tehran, Iran in November 2013 with fever, skin lesions, and dyspnea complaint from 10 days ago. He had a history of dry coughs and had been diagnosed with pneumoconiosis since 5 years earlier and had received inhaled corticosteroid and bronchodilator. But he had not a history of bacterial or fungal infection in the past.

On examination, he was alert, febrile (38.5°C), and tachypneic. Oxygen saturation without oxygen in rest was 85% (PR*1=95, RR*2=26, BP*3= 130/80). In addition, multiple inflammatory cutaneous abscess-like lesions were observed in anterior left thigh with a diameter of 5*3 cm as well as in the posterior part of the shoulder with a diameter of 2*2 cm. Also, two abscess-like lesions with a diameter of 1*1 cm were observed in the tip of the tongue and sublingual.

Chest auscultation revealed a generalized-course crackle in both lungs and sound reduction in the base of the lungs. Cardiac auscultation showed no abnormalities, and the remainder of the physical examination was normal.

Laboratory analysis results revealed leukocytosis and neutrophilia (WBC=13×10³, PMN=86%), HB=11.2, Plt=11900; also, ESR*4 level was 85, CRP*5 level was 55, creatinine=1.1, and BUN=23. Chest CT scan revealed multiple cavity lesions in the right superior lobe, left of the lingual, and inferior segments of two lobes. According to the pneumoconiosis history, comparing the latest chest CT scan results with the ones taken six month earlier showed that the cavity lesions were new (Figure 1, 2). BAL*6 for TB*7

and other microorganisms was negative. MRI with and without contrast was performed, which was normal. Sonography of soft tissue lesions showed the possibility of abscess for all lesions. All of the abscesses were drained, and smear and culture were performed. The smears showed *staphylococcus*-like Gram-positive cocci, which were confirmed as *S. aureus* based on culture and conventional microbial and biochemical tests. The patient received 2g vancomycin per day intravenously for 10 days. After a few days, the fever stopped, but anterior thigh abscess progressed.

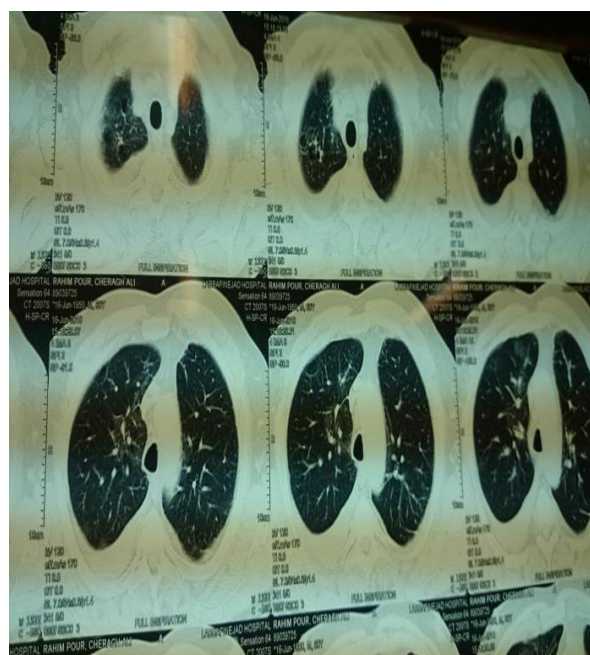


Figure 1. Chest CT scan 6 month before the onset of symptoms.

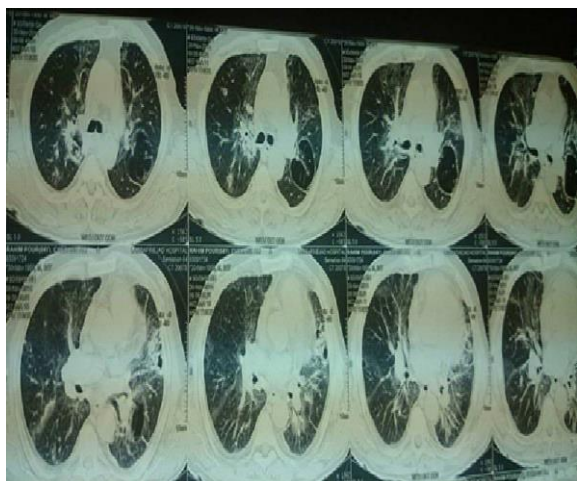


Figure 2. Chest CT scan in admission time.

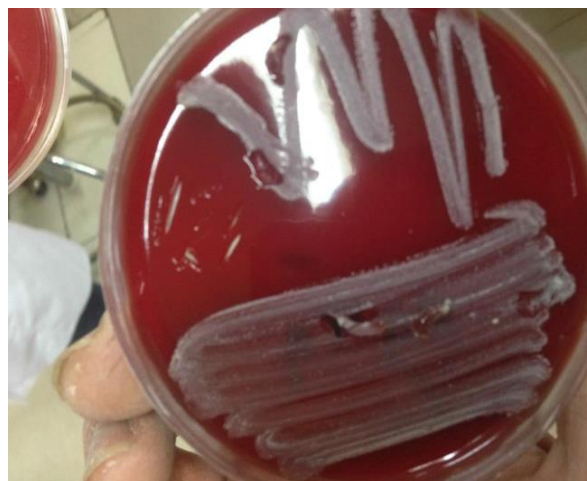

Figure 4. Culture of abscess contents.

The contents of the abscess were drained and sent for smear and culture (Figure 3, 4). Gram staining revealed the beaded branching filaments and weakly acid-fast filaments. The morphology of colonies was compatible with *Nocardia* in culturing on blood agar (BA), colombia agar with colistin, and sabouraud dextrose agar (SDA). Microbial and biochemical tests such as modified acid fast staining, catalase, growth in lysozyme, hydrolysis of casein, tyrosine, xanthine, hypoxanthine, and uric acid were used for *Nocardia* spp. confirmation. Also, using biochemical differential tests and sequence analysis of 16sRNA, the *Nocardia* spp was confirmed as *N. farcinica* IFM10152DNA in gene bank. Smear and culture for fungal infections were negative. The NBT*8 and immunoglobulin level (IgM, IgG, IgG) were within normal limits, and HIV*9 antibody assay was negative in two steps.

According to the skin lesion progression and the results of smear and culture in diagnosis of *Nocardia* skin lesions, the TMP/SMX*10 160/ 800 BD intravenously was started empirically; however, the treatment was not successful, and new skin lesions appeared, and even previous skin lesions became worse. Antibiotic resistance test was performed for isolated *Nocardia*, TMP/SMX resistance was reported, and thereby, the treatment regimen was changed to imipenem 500 mg IV (QID) and amikasin 600 mg IV daily. After two weeks, patient complained about jerky movement in his left lower extremities, and new brain MRI with and without contrast revealed multiple abscesses (Figure 5).

Due to the risk of disseminated *Nocardia* infection with cerebral involvement, the imipenem was replaced with the high dose of meropenem 2g IV (TDS), and linezolid 600 mg IV (BD)

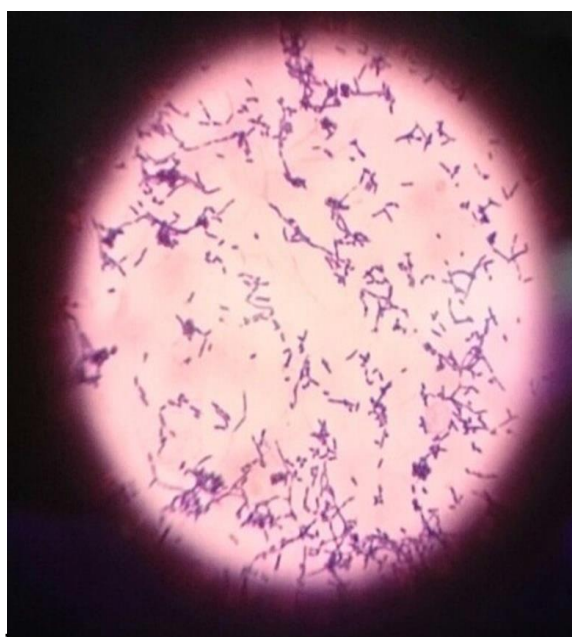


Figure 3. Gram staining of the contents of abscess with gram positive branched beaded filament.

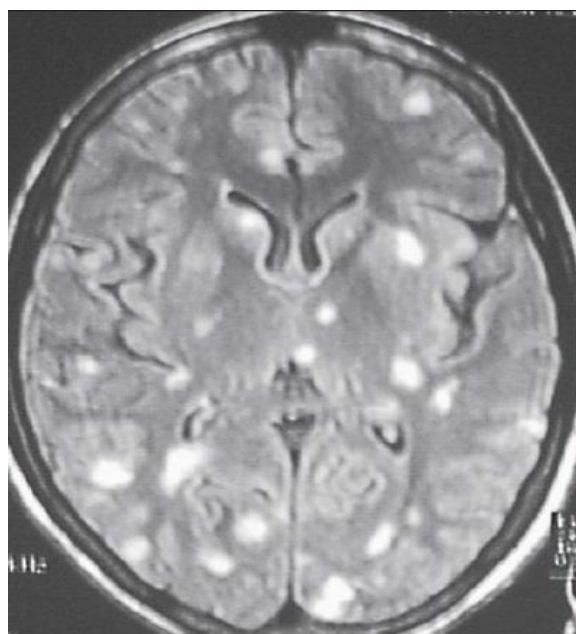


Figure 5. Brain MRI with multiple abscess.

was also added. As a result, skin abscesses were resolved, and brain and pulmonary symptoms decreased. Unfortunately, despite of clinical improvement, the patient died because of sudden respiratory distress and pulmonary thromboembolism six weeks after admission.

2. Discussion

Nocardia spp. are aerobic, Gram positive branching filamentous weakly acid-fast bacteria that live as soil saprophytes (1). *Nocardia* disease acquired by direct inoculation into the skin or inhalation of organism and nosocomial transmission is rare (4). *N. farcinica* is one the most important and common species of *Nocardia*, which is potentially lethal because of its desire to disseminate and its antibiotic resistance (4). The most common manifestation of *N. farcinica* in immunosuppressed patients is pulmonary disease (4). Rarely, *Nocardia* infections can affect an immunocompetent patient with no evidence of pulmonary complications; therefore, nocardiosis is observed more likely in immunocompromised people and people with structural lung disease, especially chronic obstructive pulmonary disease (COPD*11), or those who have a history of surgery or trauma (5). Other risk factors are corticosteroid therapy, malignancy transplantation, autoimmune disease, acute immunodeficiency syndrome, and intravenous drug abuse. In a study conducted in 2006, in a large number of cases, more risk factors were present in 94% of the patients, most of whom had used corticosteroid and immunosuppressive treatment (3). Therefore, nocardiosis usually occurs in patients who has either impaired local pulmonary defense or systemic immunosuppression and also in individual with structural lung disease, especially with chronic obstructive pulmonary disease (5), but rarely in healthy people (6). Cases of pulmonary and disseminated nocardiosis associated with alemtuzumab treatment have been reported only in patients with preexisting conditions involving immunity, including non-Hodgkin's lymphoma, Bcell lymphocytic leukemia, and organ transplant (7). In a retrospective review of 53 cases of *N. farcinica* infection, 85% of the patients had predisposing factors (8). In another study, chronic pulmonary disease was reported as the underlying condition in five cases, and only one patient had not received systemic steroid therapy (9). This patient had previously been mostly healthy except for well tolerated mild pneumoconiosis and never previously received systemic steroid treatment (9). In another study, a few cases of pulmonary nocardiosis were reported in pneumoconiosis (10). These cases highlight that pulmonary nocardiosis should also be keep in mind in pneumoconiosis. Pneumoconiosis is mainly due to exposure to inorganic dust which is retained in the lung parenchyma and inciting fibrosis (10). The clinical diagnosis of pneumoconiosis is usually based on an occupational history, chest radiographic findings, and compatible pulmonary function tests (2). *Nocardia* brain abscess has rarely been reported in an immunocompetent host (11). *Nocardia* may be recovered from CNS, blood, lung biopsy specimens or plural aspirate as well as from other organs of immunosuppressed patients. Detection of *Nocardia* is done by PCR and Real-Time PCR. In this study, PCR was used to determine the presence of *Nocardia* using primers specific for *Nocardia* 16S rRNA on the positive 27 DNA samples that were *Mycobacterium tuberculosis* negative but *Nocardia* positive. Co-trimoxazole (TMP/SMX) is generally recommended for the empirical nocardiosis treatment (3). The prevalence rate of resistance genes in Co-trimoxazole (TMP/SMX) resistant strains was as follows: sul1 and sul2,

93.4 and 78.9%, respectively; dfrA(S1) 14.7%; blaTEM-1 and blaZ, 2.6 and 2.6%, respectively; VIM-2 1.3%; aph(3')-IIIa 40.8%; ermA, ermB, mefA, and msrD, 2.6, 77.6, 14.4, and 5.2%, respectively; and tet(O), tet(M), and tet(L), 48.6, 25.0, and 3.9%, respectively (12). The susceptibility of *N. farcinica* to co-trimoxazole (TMP/SMX) varies geographically, but the comparison is confounded by the use of different methodologies (13). In recent years, linezolid as a novel oxazolidinone antibiotic has gained more and more attention in primary therapy of *Nocardia* infection. *In vitro* investigations show consistent sensitivity of all isolates of *Nocardia* species to linezolid, and *in vivo*, the linezolid penetration into the tissue is satisfactory even in the cerebral spinal fluid (7-8). Furthermore, it is suitable for long-term therapy because it can be administered not only intravenously but also orally with 100% bioavailability (8). Linezolid has little renal or hepatic toxicity and rarely has interactions with other drugs such as immunosuppressants because it is not metabolized by human cytochrome P450 (14).

3. Conclusion

Although the TMP/SMX is still drug of choice for nocardiosis treatment, in regions such as Iran, where the *Nocardia* spp. resistance against TMP/SMX is reported, it is recommended to perform the antibiotic susceptibility testing in cases applicable, and the clinicians may consider other empirical treatments options rather than TMP/SMX for patients with nocardiosis.

Abbreviations

- *1 PR= Pulse rate
- * 2 RR= Respiratory rate
- *3 BP=Blood pressure
- *4 ESR=Erythrocyte sedimentation rate
- *5 CRP= C Protein reactive
- *6 BAL=Broncho alveolar lavage
- *7 TB=Tuberosc sclerosis
- *8 NBT=Nitro blue tetrazolium
- *9 HIV=Human immunosuppressive virus
- *10TMP/SMX=Sulfamethoxazole
- *11COPD=chronic obstructive pulmonary disease

Conflict of Interests

The authors declare that there is no conflict of interests.

Acknowledgment

We thank the personnel of khatam hospital.

Authors' Contribution

Sara Abolghasemi designed the study.

Funding/Support

The cost of this research is provided by ourselves.

References

1. Budzik JM, Hosseini M, Mackinnon Jr AC, Taxy JB. Disseminated *Nocardia farcinica*: Literature review and fatal outcome in an immunocompetent patient. *Surg Infect.* 2012; 13(3):163-170.
2. Saubolle MA, Sussland D. Nocardiosis review of clinical and laboratory experience. *J Clin Microbiol.* 2003. 41(10):4497-501.
3. Brown-Elliott BA, Brown JM, Conville PS, Wallace RJ. Clinical and laboratory features of the *Nocardia* spp. based on current molecular taxonomy. *Clin Microbiol Rev.* 2006; 19(3):259-82.
4. Perfect JR, Dismukes WE, Dromer F, Goldman DL, Graybill JR, Hamill RJ, et al. Clinical practice guidelines for the management of cryptococcal disease: 2010 update by the Infectious Diseases Society of America. *Clin Infect Dis.* 2010; 50(3):291-322.
5. Roth A, Andrees S, Kroppenstedt RM, Harmsen D, Mauch H. Phylogeny of

- the genus *Nocardia* based on reassessed 16SrRNA gene sequences reveals under speciation and division of strains classified as *Nocardia asteroides* into three established species and two unnamed taxons. J Clin Microbiol. 2003; 41(2):851-856.
6. Penkert H, Delbridge C, Wantia N, wiester B, Korn T. Fulminant central nervous system nocardiosis in a patient treated with alemtuzumab for relapsing-remitting multiple sclerosis. JAMA Neurol. 2016; 73(6):757-9
 7. Boiron P, Provost F, Chevrier G, Dupont B. Review of nocardial infections in France 1987 to 1990. Eur J Clin Microbiol Infect Dis. 1992; 11(8):709-14.
 8. McNeil M, Brown J. *Nocardia* species (Nocardiosis). Antimicrob Ther Vaccine, 2002; 1:481-500.
 9. Wade WA, Petsonk EL, Yong B, Mogri I. Severe occupational pneumoconiosis among west virginian coal miners: One hundred thirty-eight cases of progressive massive fibrosis compensated between 2000 and 2009. Chest. 2011; 139:1458-62.
 10. Kim S, Lee KL, Lee DM, Jeong JH, Moon SM, Seo YH, et al. *Nocardia* brain abscess in an immunocompetent patient. Infect Chemother. 2014; 46(1):45-9
 11. Tremblay J, Thibert L, Alarie I, Valiquette L, P  pin J. Nocardiosis in Quebec, Canada, 1988–2008. Clin Microbiol Infect. 2011; 17(5):690-6.
 12. Valdezate S, Garrido N, Carrasco G, Villal  n P, Medina-Pascual MJ, Sa  ez-Nieto JA. Resistance gene pool to co-trimoxazole in non-susceptible *Nocardia* strains. Front Microbiol. 2015; 6:376
 13. Vigan   SM, Edefonti A, Ferrareso M, Ranzi ML, Grossi P, Righini A, et al. Successful medical treatment of multiple brain abscesses due to *Nocardia farcinica* in a paediatric renaltransplant recipient. Pediatr Nephrol. 2005; 20(8):1186-8
 14. Brown-Elliott BA, Brown JM, Conville PS, Wallace RJ. Clinical and laboratory features of the *Nocardia* spp. based on current molecular taxonomy. Clin Microbiol Rev. 2006; 19(2): 259-82.

How to cite this article: Aghajanpour S., Abolghasemi S., Dabiri H., Tehrani Sh., Divsalar F. Disseminated *Nocardia Farcinica* Infection in a Patient with Pneumoconiosis, Infection, Epidemiology and Microbiology. 2017; 3(4): 143-146.