

Anti-NMDA Receptor Encephalitis Associated with SARS-CoV-2 Infection in the COVID-19 Pandemic: A Systematic Review

ARTICLE INFO

Article Type Review Article

Authors

Justyna Jachman-Kapulka, MD^{1*}
Marta Rorat, PhD²

¹ Department of Internal Medicine and Rheumatology, J. Gromkowski Specialist Regional Hospital, Wrocław, Poland

² Department of Social Sciences and Infectious Diseases, Medical Faculty, Wrocław University of Science and Technology, Poland

* Correspondence

Department of Internal Medicine and Rheumatology, J. Gromkowski Specialist Regional Hospital, Wrocław, Poland.
E-mail: justyna.jachman@gmail.com

How to cite this article

Jachman-Kapulka J., Rorat M. Anti-NMDA Receptor Encephalitis Associated with SARS-CoV-2 Infection in the COVID-19 Pandemic: A Systematic Review. Infection Epidemiology and Microbiology. 2025;11(2): 189-203.

Article History

Received: June 01, 2024
Accepted: August 21, 2024
Published: June 22, 2025

ABSTRACT

Background: Severe acute respiratory syndrome coronavirus 2 (SARS-CoV-2) is associated with neurological complications, like various autoimmune encephalitis (AE) types. This study aimed to identify and analyze COVID-19 cases diagnosed with anti-N-methyl-D-aspartate receptor (NMDAR) encephalitis (anti-NMDARE). **Materials & Methods:** This research summarized all post-pandemic reports. The review was conducted based on PRISMA (preferred reporting items for systematic reviews and meta-analyses) 2020 guidelines. Electronic databases were search using search terms to find anti-NMDARE cases associated with COVID-19.

Findings: After analyzing 649 records, 16 patients (ten women and six men) with a median age of 19.5 years were identified. All AE cases were confirmed by the presence of anti-NMDAR IgG, dominant behaviour and mental status changes, psychiatric symptoms, epileptic seizures, movement disorders, and sleep and speech problems. Abnormalities were more common in electroencephalography (EEG) and cerebrospinal fluid (CSF) than in brain MRI scans. All patients received first-line guideline-based therapy (intravenous methylprednisolone, intravenous immunoglobulin, plasma exchange), and five patients received second-line immunotherapy (rituximab, azathioprine, cyclophosphamide). Nine out of 16 patients had complete recovery or significant improvement.

Conclusion: Considering the magnitude of the pandemic and the few anti-NMDAR encephalitis cases temporally diagnosed with COVID-19, this association was relatively rare. The appearance of characteristic features of encephalitis during SARS-CoV-2 infection necessitates further diagnostic tests, especially detection of auto-antibodies and possible neoplasm, since earlier diagnosis and treatment provide a better prognosis. This review highlights the need for further investigation into the co-occurrence of anti-NMDARE with COVID-19, long-term clinical outcomes, and possible relapses.

Keywords: SARS-CoV-2, NMDA receptor, Autoimmune encephalitis, COVID-19 vaccination, Immunotherapy

CITATION LINKS

[1] Mao L, et al. Neurologic manifestations... [2] Studart-Neto A, et al. Neurological... [3] Misra S, et al. Frequency of... [4] Broła W, Wilski M. Neurological... [5] Ellul MA, et al. Neurological... [6] Wu Y, et al. Nervous... [7] Baig AM, et al. Evidence of... [8] Yassin A, Nawaiseh M, et al. Neurological... [9] Harapan BN, Yoo HJ. Neurological... [10] Nabizadeh F, et al. Autoimmune... [11] Guedes BF. NeuroCOVID-19... [12] Pinzona RT, et al. Persistent... [13] Xue H, et al. Autoimmune... [14] Stoian A, et al. Autoimmune... [15] Islam MA, et al. Encephalitis in... [16] Dalmau J, Graus F. Antibody... [17] Kayser MS, Dalmau J. Anti-NMDA... [18] Miya K, et al. Anti-NMDAR... [19] Titulaer MJ, et al. Treatment and... [20] Dalmau J, et al. An update... [21] Graus F, et al. A clinical approach... [22] Wang H. Anti-NMDA... [23] Schabitz WR, et al. VZV brainstem... [24] Vasilevska V, et al. Molecular mimicry... [25] McHattie AW, et al. Palilalia as... [26] Mukherjee J, et al. Co-occurrence... [27] Lee H, et al. Anti-N... [28] Allahyari F, et al. A case report... [29] Alvarez Bravo G, Ramio IT. Anti-NMDA... [30] Alvi JR, et al. Post COVID... [31] Burr T, et al. N-methyl... [32] Derakhshani F, et al. Autoimmune... [33] Kaur P, et al. Infantile anti... [34] Monti G, et al. Anti-NMDA... [35] Panariello A, et al. Anti-NMDA... [36] Saini L, et al. Post-COVID-19... [37] Sanchez-Larsen A, et al. Anti-NMDA-R... [38] Sanchez-Morales AE, et al. Neurological... [39] Sarigecili E, et al. Pediatric... [40] Valadez-Calderon J, et al. Co-expression... [41] Joubert B, Dalmau J. The role... [42] Swayne A, et al. Analysing... [43] Armangue T, et al. Herpes... [44] Armangue T, et al. Frequency... [45] Mohammad SS, et al. Herpes... [46] Leypoldt F, et al. Herpes... [47] Salovin A, et al. Anti-NMDA... [48] Schabitz WR, et al. VZV... [49] Ma J, Zhang T, Jiang L. Japanese... [50] Xu CL, et al. Anti-N-methyl... [51] Ioannidis P, et al. Anti-NMDA... [52] Moloney PB, et al. Possible... [53] Pacheco-Herrero M, et al. Elucidating... [54] Wang H. COVID-19... [55] Muñoz-Lopetegi A, et al. Neurologic... [56] Emekli AS, et al. Anti-GAD... [57] Salari M, et al. Autoimmune... [58] Martin S, et al. Anti-NMDA... [59] Flannery P, et al. Acute... [60] Abdelhady M, Husain MA, et al. Encephalitis... [61] Martin S, et al. Anti-NMDA...

Introduction

In addition to affecting the respiratory system, severe acute respiratory syndrome coronavirus 2 (SARS-CoV-2) could attack other organs and systems, including the nervous system which is affected in approximately one-third of coronavirus disease 2019 (COVID-19) patients ^[1-4]. Neurological manifestations may involve both the central nervous system (CNS) and the peripheral nervous system (PNS). They are primarily caused by non-specific complications of the systemic disease, hypercoagulable state, direct viral infection, hypoxia, and immune-mediated injury ^[1, 5-7].

The most common neurological manifestations are headache, dizziness, altered mental status/confusion/delirium, myalgia, anosmia, ageusia, ataxia, or seizures. Neurological complications of COVID-19 include: cerebrovascular diseases, encephalopathy, myopathy, acute disseminated encephalomyelitis (ADEM), polyneuropathy, Guillain-Barré syndrome (GBS), Miller-Fisher syndrome (MFS), meningitis, encephalitis, and meningoencephalitis ^[8-10].

Neurological complications of COVID-19 could be para-infectious or post-infectious, with neurological symptoms persisting or developing in the post-acute phase, creating a condition known as "long COVID" according to the World Health Organization (WHO) ^[5, 11, 12].

Among diverse neurological complications, autoimmune encephalitis (AE) in the course of COVID-19 has been described in several articles ^[10, 13-15]. Anti-N-methyl-D-aspartate (NMDA) receptor encephalitis is the most common type of AE, in which IgG auto-antibodies recognize and bind to the GluN1 subunit of the NMDAR, inducing reversible internalization of receptors in the synaptic and extrasynaptic space ^[16, 17]. NMDA receptor (NMDAR) is mainly involved in proper neuronal network

development, synaptic plasticity, and higher brain function. NMDA receptor subunits are widely distributed in the brain, especially in the limbic system ^[18]. Therefore, anti-NMDA receptor (anti-NMDAR) encephalitis manifests in various ways, mainly changes in mood and behaviour, psychosis, seizures, autonomic dysregulation, encephalopathy, and rarely movement disorders ^[16, 17, 19]. This type of encephalitis, which was first reported in 2007, is rare (1.5 cases per million people per year) ^[20]. In 2016, diagnostic criteria were defined for its probable or definite diagnosis. The criteria for its probable diagnosis include: 1) rapid onset of at least four major groups of symptoms including abnormal behavior or cognitive dysfunction, speech impairment, seizures, movement disorder, decreased level of consciousness, autonomic dysfunction, and central hypoventilation; 2) one or more positive laboratory tests, including abnormalities in electroencephalography (EEG) and/or cerebrospinal fluid (CSF) with pleocytosis or oligoclonal bands; 3) onset of three groups of symptoms and identification of a systemic teratoma; and 4) exclusion of recent history of herpes simplex virus encephalitis or Japanese encephalitis ^[21]. Whereas the criteria for its definite diagnosis include: 1) one or more major groups of symptoms and the presence of IgG GluN1 antibodies (antibody testing should include CSF; if only serum is available, confirmatory tests should be included) and 2) exclusion of other types of encephalitis mentioned above ^[21].

According to Dalmau et al. (2019), 80% of patients have a good prognosis after immunotherapy, with 12% of relapses occurring within the first 2 years after the initial episode ^[20]. Anti-NMDA receptor encephalitis is more frequent among young females (81%) with a median age of 21 years ^[20]. It may appear as a paraneoplastic disorder, mostly with ovarian teratoma, or

may be related to various vaccinations [16, 17, 19, 22]. Studies have shown that anti-NMDAR encephalitis (anti-NMDARE) could be triggered by viral infections, mainly herpes simplex virus (HSV), Japanese encephalitis virus (JEV), and varicella-zoster virus (VZV) [22, 23]. Moreover, during the COVID-19 pandemic, some studies reported cases of anti-NMDAR encephalitis probably triggered by SARS-CoV-2 infection.

Considering COVID-19 as a global problem with a set of complications and long-term consequences that are still unknown, this systematic review was conducted to identify and summarize published cases of SARS-CoV-2 infection with anti-NMDAR encephalitis.

Objectives: This study aimed to describe the association of anti-NMDA receptor encephalitis with SARS-CoV-2 infection and to assess the clinical course, especially in comparison with anti-NMDAR encephalitis without concomitant COVID-19.

Materials and Methods

This systematic review was conducted in line with the rules set by PRISMA (preferred reporting items for systematic reviews and meta-analyses) 2020 (<http://www.prisma-statement.org/>). PubMed, Science Direct, and Google Scholar databases were searched (last search: 8 July 2023) to identify published articles (original articles, case reports, clinical letters, letters to the editor, and review articles) reporting COVID-19 cases with associated anti-NMDA receptor encephalitis using the following keywords: "COVID-19", "SARS-CoV-2", "NMDAR encephalitis", "anti-NMDAR encephalitis" and "NMDA receptor encephalitis". A total of 649 records were identified: 641 records in all databases (12 records in Pub Med, 597 records in Google Scholar, and 32 records in Science Direct) and eight records in a previous review [24]. Published cases in En-

glish with confirmed SARS-CoV-2 infection and symptoms of anti-NMDAR encephalitis that developed simultaneously with or after COVID-19 were included in this study. Encephalitis was detected by the diagnostic criteria suggested by Graus et al. (2016) [21] and the presence of anti-NMDAR antibodies in CSF and/or serum. Cases in whom SARS-CoV-2 or anti-NMDAR encephalitis was not confirmed, or in whom anti-NMDAR encephalitis occurred prior to COVID-19 were excluded [25]. Cases with anti-NMDARE evidently triggered by the COVID-19 vaccination were also excluded. After screening and applying the eligibility and inclusion criteria detailed above, 15 studies comprising a total of 16 cases were selected. The search strategy process is shown in Figure 1.

Data extracted from the case descriptions were: age, gender, medical comorbidities, diagnostic methods (SARS-CoV-2 tests, brain imaging results, EEG, CSF analysis, auto-antibodies, etc.), general and neuropsychiatric symptoms, time intervals between COVID-19 and encephalitis onset, treatments, and clinical outcomes. The reported cases are presented in Table 1 [26-40].

Findings

The literature review led to the identification of 16 patients in different periods of the SARS-CoV-2 pandemic, among them ten cases were female, and six cases were male in the age range of 10 months to 65 years (nine adults) and a median age of 19.5 years, they were diagnosed with SARS-CoV-2 and anti-NMDAR encephalitis based on the presence of anti-NMDAR IgG in CSF (nine cases), serum (one case), or both (six cases); specific clinical presentations; and additional laboratory test results. Other comorbidities were reported in four cases (patient no. 2, 10, 11, 13), such as mild hypertension, progressive dementia, drug addiction, and epilepsy. The most common presentations of SARS-CoV-2

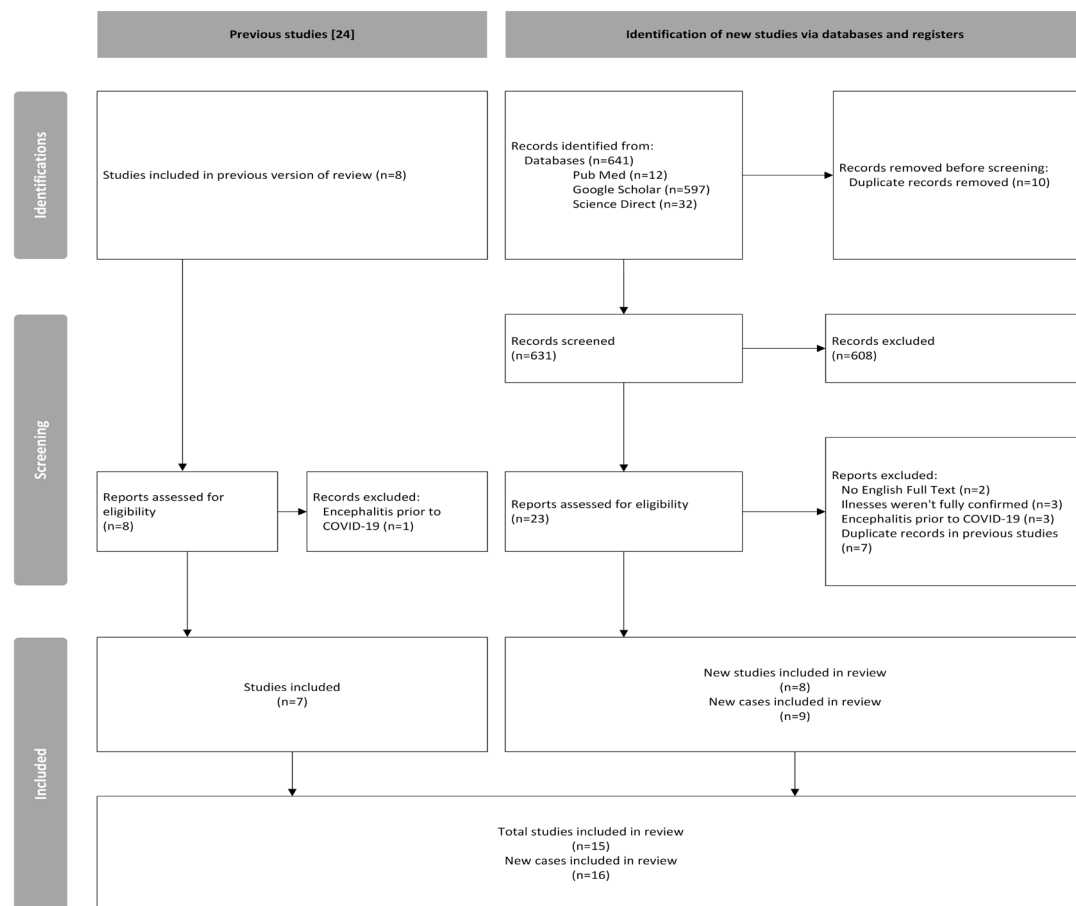


Figure 1) PRISMA flow diagram illustrating selection procedure of the case reports for our systematic review with 15 studies (16 cases) included.

infection were mild symptoms such as fever and cough. In four patients (no. 1, 4, 5, 11), the disease took a more severe course with complications such as pneumonia, bilateral pulmonary embolism with intensive care unit (ICU) hospitalization, or general dysautonomia.

Two patients (no. 2, 14) had asymptomatic SARS-CoV-2 infection. One patient (no. 3) was in the phase after the third dose of the SARS-CoV-2 vaccination. Three women (no. 3, 5, 8) were newly diagnosed with ovarian teratoma.

In these cases, encephalitis manifestations appeared from the first day of COVID-19 to 8 weeks after SARS-CoV-2 detection or symptom onset.

Changes in behaviour, mental status, and/or consciousness in each patient were regarded primarily as initial signs. Psychiatric

symptoms were dominant in nine cases (no. 1, 3, 4, 5, 10, 11, 13, 15, 16; 8 adults), such as depression, delusions, hallucinations, confabulations, psychosis, suicidal ideation, and catatonia.

Frequent neurological manifestations of anti-NMDAR encephalitis were as follows: epileptic seizures (both focal and generalized status epilepticus in no. 10 and 16), which were present in 11 patients (no. 1, 4, 5, 6, 7, 8, 10, 13, 14, 15, 16; 5 children), and movement disorders including orofacial dyskinesia, chorea-dystonic movements, dystonia, athetosis, and automatisms, which were present in ten patients (no. 1, 5, 6, 7, 9, 10, 11, 12, 14, 15; 5 children).

Furthermore, the majority of patients experienced sleep and speech disorders. The frequency of symptoms of anti-NMDA receptor encephalitis is presented in Figure 2.

Table 1) Summary of the cases with anti-NMDA receptor encephalitis associated with SARS-CoV-2 infection published in the literature

No.	Publication	Age, Sex	Medical Comorbidities/ Vaccination Status	SARS-CoV-2 and Other Diagnostic Results	General and Respiratory Symptoms	Onset of Encephalitis from COVID-19 Presentation	Neurological and Psychiatric Symptoms	Encephalitis Diagnostic Results	SARS-CoV-2 and Neurological Treatment	Clinical Outcome
1.	Mukherjee et al. (2022) India [26]	21 Y, F	NR	SARS-CoV-2 RT-PCR: positive Chest CT: right middle and lower lobe consolidation Abdomen and pelvis USG: normal Blood analysis: high level of d-dimer, ESR, and CRP	Fever, tachypnoeic	Initial presentation	Headache, giddiness, unsteady gait, right focal seizures, confusion, altered sleep, visual hallucinations, mutism, disorientation, terminal neck rigidity, right hemiparesis, dystonic posturing of all limbs	Brain MRI: T2-FLAIR hyperintensity in bilateral caudate, putamen, frontal and parietal, insular, and temporal lobe cortices with mild diffusion restriction and motor cortex sparing and pachymeningeal enhancement EEG: intermittent theta slowing in bilateral temporal regions CSF: normal general analysis Anti-NMDAR antibodies: positive in both CSF and serum	Antibiotics, remdesivir, phenytoin, baclofen, trihexyphenidyl, plasma exchange	Slow clinical improvement with no seizures
2.	Mukherjee et al. (2022) India [26]	65 Y, F	5 years history of slowly progressive impairment of cognitive functions	SARS-CoV-2 RT-PCR: positive Chest CT: normal Abdomen and pelvis USG: normal Blood analysis: normal	None	Initial presentation	Rapid worsening of dementia, asymmetrical rigidity (left>right)	Brain MRI: bilateral cerebral atrophy, hyperintensity in bilateral subcortical, deep and periventricular white matter EEG: sharp waves in the right-sided posterior region CSF: normal general analysis Anti-NMDAR antibodies: positive in serum but negative in CSF	Remdesivir, IVMP, donepezil	Improved partially in cognition, full improvement in rigidity
3.	Lee et al. (2022) Republic of Korea [27]	21 Y, F	None/ After 3 rd dose of BNT162b2 vaccination against SARS-CoV-2 four months ago	SARS-CoV-2 RT-PCR: positive Abdomen and pelvis CT: teratoma in right ovary Blood analysis: normal	NR	After 3 days	Short-term memory loss, abnormal behaviour, uncoherent speech, psychosis, anxiety	Brain MRI: FLAIR contrast-enhanced lesions in the cerebellum and hippocampus EEG: diffuse beta wave activity with rare sharp waves in both temporal lobes CSF: high opening pressure, elevated protein level, lymphocytic pleocytosis Anti-NMDAR antibodies: positive in both CSF and serum	IVMP, IVIG, teratoma removal	Discharged with improvement in psychosis; but with memory impairment

No.	Publication	Age, Sex	Medical Comorbidities/ Vaccination Status	SARS-CoV-2 and Other Diagnostic Results	General and Respiratory Symptoms	Onset of Encephalitis from COVID-19 Presentation	Neurological and Psychiatric Symptoms	Encephalitis Diagnostic Results	SARS-CoV-2 and Neurological Treatment	Clinical Outcome
4.	Allahyari et al. (2021) Iran ^[28]	18 Y, F	None	SARS-CoV-2 RT-PCR: positive in CSF Anti-SARS-CoV-2 IgM: positive in serum Chest CT: peripheral ground-glass opacities in lower lung zones Blood analysis: normal neutrophilia, lymphopenia, and CRP	Low-grade fever, dry cough, shortness of breath, hypotonia, tachycardia, tachypnoea, oxygen saturation 90%	Initial presentation	Depression, anhedonia, lack of concentration, generalized tonic-clonic seizures, confused state, minor meningismus, altered mental status	Initial brain CT: generalized brain oedema Brain MRI after 3 days: normal CSF: elevated protein level, lymphocytic pleocytosis Anti-NMDAR antibodies: positive in CSF	Antibiotics, acyclovir, remdesivir, lopinavir/ritonavir, interferon b1a, sodium valproate, IVMP, IVIG, oral corticosteroids	Full recovery after 2 months of hospitalization
5.	Alvarez-Bravo & Ramio (2020) Spain ^[29]	30 Y, F	NR	SARS-CoV-2 RT-PCR: positive Initial chest X-ray: normal Detected left ovarian teratoma: method NR	Fever, subsequently hypovolemic shock and intra-abdominal infection after removing left ovarian teratoma, thrombosis of left iliac vein, and bilateral pulmonary embolism attributed to SARS-CoV-2 with ICU admission	Initial presentation	Paranoid ideation, psychomotor agitation, visual hallucinations, dysarthria with dysprosody, focal and generalized seizures in evolution: decreased level of consciousness, buccolingual dyskinesia, choreo-dystonic movements in the right hand and afterwards generalized, blepharoclonus	Initial brain CT scan: normal Brain MRI after a few days: hyperintensities in the left hippocampus EEG: epileptic discharges in the left frontotemporal region In evolution: delta brush pattern with spike-and-wave discharges in anterior regions CSF: elevated protein level, lymphocytic pleocytosis Anti-NMDAR antibodies: positive in both CSF and serum	Hydroxychloroquine, lopinavir/ritonavir/sodium valproate, IVMP, IVIG, lacosamide, perampanel Due to insufficient improvement: rituximab, BZD, olanzapine, teratoma removal	Hypoproposexia, memory disorders, emotional lability
6.	Alvi & colleagues (2022) Pakistan ^[30]	13 Y, F	NR / Not vaccinated for COVID-19	SARS-CoV-2 antibody: positive in serum Abdomen and pelvic MRI: normal Blood analysis: hyperthyroidism without thyroid antibodies	Tachycardia, high blood pressure	NR	Aggression, irritability with disturbed sleep wake cycle, irrelevant talk and memory loss, generalized tonic-clonic seizures, dystonic posture, oro-facial dyskinesia, dystonia of ocular muscles, generalized upper motor neuron signs	Brain MRI: normal EEG: slow background with delta brush pattern CSF: normal general analysis Anti-NMDAR antibodies: positive in CSF	Anti-thyroid drug, IVMP, plasma exchange Due to insufficient improvement: rituximab, oral corticosteroids, levetiracetam	Improved movements and conscious level, with residual deficit in executive function

No.	Publication	Age, Sex	Medical Comorbidities/ Vaccination Status	SARS-CoV-2 and Other Diagnostic Results	General and Respiratory Symptoms	Onset of Encephalitis from COVID-19 Presentation	Neurological and Psychiatric Symptoms	Encephalitis Diagnostic Results	SARS-CoV-2 and Neurological Treatment	Clinical Outcome
7.	Burr et al. (2020) USA [31]	23 months, F	None	SARS-CoV-2 RT-PCR: positive Anti-SARS-CoV-2 IgG: positive in serum Blood analysis: normal ESR and CRP	No respiratory symptoms General symptoms: fever, dehydration, fussiness, decreased oral intake, constipation	Initial presentation	Sleep and talk disturbances, mood lability, hyperkinetic movements of the arms, legs, and head, seizures, encephalopathy	Brain MRI: normal CSF: mild lymphocytic pleocytosis Anti-NMDAR antibodies: positive in both CSF and serum	Lorazepam, IVMP, levetiracetam, IVIG	Recovery 2 weeks after discharge
8.	Derakshani & colleagues (2023) Iran [32]	11 Y, F	NR	Anti-SARS-CoV-2 IgG: positive in serum Abdominal USG: teratoma in right ovary Blood analysis: normal	Fever, tachycardia, rushes on the trunk and limbs	Initial presentation	Behaviour disorders, cognition impairment, seizures, confusion, subsequently bedridden, no cognitive attention, and unable to talk	Brain MR: normal EEG: generalized slowing CSF: normal general analysis Anti-NMDAR antibodies: positive in both CSF and serum	IVMP, IVIG, plasma exchange, levetiracetam, clobazam, oral corticosteroids Due to no response: rituximab, teratoma removal	Discharged with full recovery after one month
9.	Kaur & colleagues (2022) India [33]	10 months, M	None	Anti-SARS-CoV-2 IgG: strongly positive in serum Abdomen and pelvis CT: normal Echocardiography: normal Blood analysis: elevated WBC, normal CRP	Upper respiratory tract infection, fever, and loose stools	After 40 days	Poor feeding, irritability, 2 episodes of convulsions, loss of pre-morbidly normal eye contact, poor interaction with caregivers, peri-oral dyskinesias, bilateral striatal toe, on the next day generalized and oro-linguo-buccal dystonia with athetosis	Brain MRI: normal CSF: lymphocytic pleocytosis Anti-NMDAR antibodies: positive in CSF	IVMP, IVIG, clonidine, baclofen, clonazepam Due to insufficient improvement: rituximab and azathioprine, following cyclophosphamide, oral corticosteroids	At the time of last follow-up: extrapyramidal movements were well controlled and regaining age-appropriate milestones

No.	Publication	Age, Sex	Medical Comorbidities/ Vaccination Status	SARS-CoV-2 and Other Diagnostic Results	General and Respiratory Symptoms	Onset of Encephalitis from COVID-19 Presentation	Neurological and Psychiatric Symptoms	Encephalitis Diagnostic Results	SARS-CoV-2 and Neurological Treatment	Clinical Outcome
10	Monti et al. (2020) Italy [34]	50 Y, M	Mild hypertension	SARS-CoV-2 RT-PCR: positive Chest X-ray and chest CT scan: normal Total-body CT and PET: normal Blood analysis: increased IL-6, normal CRP and WBC	Fever	Initial presentation	Confabulations and delirious ideas After 4 days: focal motor seizures, impaired awareness, oro-facial dyskinesia, autonomisms, and refractory status epilepticus (RSE) with ICU admission	Brain MRI: normal EEG: delta brush pattern, anterior sub-continuous theta activity with progressive improvement CSF: pleocytosis, mildly elevated protein level, increased IL-6 and IL-8, presence of oligoclonal bands Anti-NMDAR antibodies: positive in CSF but negative in serum	Hydroxychloroquine, lopinavir/ ritonavir, diazepam, valproic acid, lacosamide, antiepileptic treatment and anaesthetics, IVMP, IVIG, plasma exchange	Discharged 4 months after onset in good condition with autonomy without neurological deficits
11	Panariello et al. (2020) Italy [35]	23 Y, M	Substance use disorder	COVID-19 positive: tests NR Chest X-ray: bilateral ground glass opacities Chest CT: patchy bi-basilar consolidations Blood analysis: increased CRP, WBC, and D-dimer	Fever, desaturation (90% O ₂ saturation in inhaled air) 3 weeks later: dysautonomia (fluctuations in respiratory rate, blood pressure, cardiac rhythm, body temperature)	Initial presentation	Anxiety, psychomotor agitation, auditory hallucinations, persecutory delusions, global insomnia, confusion, speech and thought disorganization Within second week: non-verbal, non-responsive to commands 3 weeks later: severe dysphagia, dyskinesia, deterioration of mental status	Brain CT: normal EEG: theta activity (6 Hz), unstable, nonreactive to visual stimuli and without asymmetries CSF: normal general analysis, increased IL-6 Anti-NMDAR antibodies: positive in CSF	Antibiotic prophylactic therapy, hydroxychloroquine, darunavir/ cobicistat, antipsychotics, BZD, valproate for seizure prophylaxis, high doses of dexamethasone, IVIG	Clinical improvement
12.	Saini et al. (2022) India [36]	4 Y, F	None	SARS-CoV-2 antibody: positive in serum Blood analysis: high inflammatory markers in serum	Fever, cough, coryza	After 8 weeks	Altered sensorium, orofacial dyskinesia, choreoathetoid movements, pelvic thrust, encephalopathy; 5 points in mRS at admission	CSF: normal general analysis Anti-NMDAR antibodies: positive in CSF	IVMP, IVIG	3 points in mRS after 3 months

No.	Publication	Age, Sex	Medical Comorbidities/ Vaccination Status	SARS-CoV-2 and Other Diagnostic Results	General and Respiratory Symptoms	Onset of Encephalitis from COVID-19 Presentation	Neurological and Psychiatric Symptoms	Encephalitis Diagnostic Results	SARS-CoV-2 and Neurological Treatment	Clinical Outcome
13.	Sanchez-Larsen et al. (2023) Spain ^[37]	22 Y, F	Non-lesion focal right frontal lobe epilepsy in monotherapy with acceptable control of seizures	COVID-19 positive; tests NR Total-body CT and FDG-PET: normal	Mild flu-like symptoms	After 5 days	Focal to bilateral tonic-clonic seizures, severe anxiety, dysphoric mood, insomnia, motor aphasia 3 weeks later: recurrence of seizures, bradyphrenia, delusions with visual hallucinations and psychomotor agitation	Brain MRI: normal EEG: frontal intermittent rhythmic delta activity (FIRDA) FDG-PET: diffuse hypometabolism in the cerebral cortex CSF: small pleocytosis Anti-NMDAR antibodies: positive in both CSF and serum	Antiepileptic treatment, BZD, antipsychotics, IVMP, IVIG, after FDG-PET received rituximab	Gradual improvement compared to her baseline status
14.	Sanchez-Morales et al. (2021) Mexico ^[38]	14 Y, M	None	SARS-CoV-2 RT-PCR in CSF: positive Anti-SARS-CoV-2 IgG antibodies: positive in CSF but negative in serum	None	NR	Altered behaviour and mental status, seizures, insomnia, orolingual dyskinesias	CSF: normal general analysis Anti-NMDAR antibodies: positive in CSF	IVMP, IVIG	A partial recovery of the neurologic symptoms with seizures control, psychiatric symptoms persistence
15.	Sarıgeçeli et al. (2021) Turkey ^[39]	7 Y, M	None	SARS-CoV-2 RT-PCR: positive Blood analysis: increased CRP, lymphopenia	Tachycardia	Initial presentation	Ataxia, wide-based gait, deep tendon areflexia, somnolence, seizures, subsequently choreiform movements in all limbs, tongue protrusion, bruxism, lip smacking, agitation, catatonia, echolalia, focal seizure on 26 day of hospitalization	Brain MRI initial and control: normal CSF: normal general analysis Awake and sleep EEGs: encephalopathic wide-spread delta waves Anti-NMDAR antibodies: positive in CSF	Antiepileptic, antiviral and antibiotic treatment, IVMP, IVIG, plasma exchange, oral corticosteroids	Level of consciousness, oral intake and involuntary movements gradually improved; discharged; mildly ataxic
16.	Valadez-Calderton et al. (2022) Mexico ^[40]	28 Y, M	None	COVID-19 positive; tests NR	Mild symptoms of COVID-19	After 2 weeks	Somnolence, incoherent speech, auditory hallucinations, suicidal ideation, generalized tonic-clonic seizures, catatonic symptoms 2 days later; status epilepticus	Brain MRI: T2 FLAIR and DWI hyperintensities in the bilateral anterior cingulate cortex and temporal lobes EEG: subcortical dysfunction in frontal, temporal, and occipital regions CSF: normal general analysis Anti-GAD 65/67 antibodies: positive in CSF Anti-NMDAR antibodies: positive in CSF	Antiepileptic and antiviral treatment, IVMP, IVIG	Clinical improvement At six week follow-up: still showing mood changes, irritability, agitation episodes

Abbreviation: Y: years, F: female, M: male, NR: not reported, RT-PCR: reverse-transcription polymerase chain reaction analysis, SARS-CoV-2: severe acute respiratory syndrome coronavirus 2, CT: computed tomography, USG: ultrasonography, ESR: erythrocyte sedimentation rate, CRP: C-reactive protein, MRI: magnetic resonance imaging, T2 FLAIR: T2-weighted, fluid-attenuated inversion recovery, EEG: electroencephalography, CSF: cerebrospinal fluid, anti- NMDAR: anti- N-methyl-D aspartate receptor, IVMP: intravenous methylprednisolone, IVIG: intravenous immunoglobulin, Anti-SARS-CoV-2 IgM: anti severe acute respiratory syndrome coronavirus 2 immunoglobulin M, ICU: intensive care unit, BZD: benzodiazepines, WBC: white blood cells, IL-6: interleukin-6, IL-8: interleukin-8, FDG-PET: fluorodeoxyglucose-positron emission tomography, mRS: modified ranking scale, FDG-PET: fluorodeoxyglucose-positron emission tomography, DWI: diffusion-weighted imaging, Anti-GAD 67/65: anti- glutamic acid decarboxylase 67/65

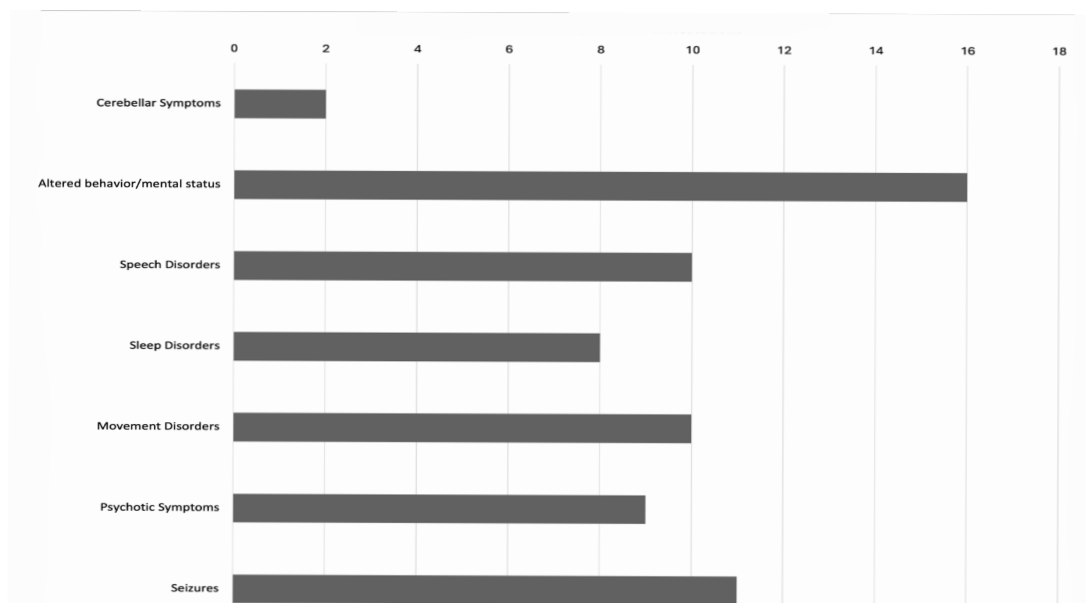


Figure 2) The neurological manifestations of anti-NMDA receptor encephalitis associated with SARS-CoV-2 infection among the analyzed cases (numbers).

In only four cases (no. 1, 2, 5, 16; all adults), brain magnetic resonance imaging (MRI) scans showed abnormalities which could be related to autoimmune encephalitis; in addition, in one case (no. 13), a fluorodeoxyglucose-positron emission tomography (FDG-PET) scan revealed diffuse hypometabolism in the cerebral cortex. Changes in EEG examinations were more frequent and detected in 11 patients (no. 1, 2, 3, 5, 6, 8, 1, 11, 13, 15, 6; 3 children), which were mainly related to theta and delta slowing, epileptic sharp waves, or encephalopathic patterns. In seven cases (no. 3, 4, 5, 7, 9, 10, 13; 2 children), abnormalities in CSF were noticed, including elevated protein level and/or lymphocytic pleocytosis. In one patient (no. 16), anti-glutamic acid decarboxylase 65/67 (anti-GAD 65/67) antibodies were found in CSF alongside anti-NMDAR antibodies.

Remdesivir was administered to three patients during the COVID-19 treatment (no. 1, 2, 4); in addition to antibiotics, antiviral drugs and hydroxychloroquine were administered in some cases. Besides antiepileptic or antipsychotic drugs, all patients received guideline-based immunotherapy due to AE. Also, 15 patients (beside no. 1) received

corticosteroids, mainly intravenous methylprednisolone (IVMP), and 13 patients (beside no. 1, 2, 6) received intravenous immunoglobulin (IVIG). Moreover, five patients (no. 1, 6, 8, 10, 15; 3 children) had plasma exchange. Second-line immunotherapy was administered in five patients (no. 5, 6, 8, 9, 13; 3 children); all received rituximab; in addition, one infant (no. 9) received azathioprine and finally cyclophosphamide, which led to improvement. Three women (no. 3, 5, 8) with ovarian teratoma underwent surgery to remove tumours.

Only four patients (no. 4, 7, 8, 13) recovered completely following treatment. Five patients (no. 1, 2, 9, 10, 11; 1 child) experienced significant improvement, while in seven cases (no. 3, 5, 6, 12, 14, 15, 16), some improvement was observed, but neurological or psychiatric symptoms persisted and were still present at the time of the last follow-up.

Discussion

Many studies have shown an association between viral infections and neurological inflammatory diseases^[41], including autoimmune encephalitis^[16,42]. In particular, herpes simplex virus encephalitis (HSVE) has been

found to trigger anti-NMDAR encephalitis with a more severe clinical course and worse outcome than classical none-triggered encephalitis in moderately elderly individuals with a female predominance. HSV triggers anti-NMDAR encephalitis probably by an inflammatory reaction and changes, disruption of the blood-brain barrier (BBB), or increased brain vulnerability [42-46]. Also, past non-encephalitic HSV-1 infection is supposed to be associated with anti-NMDAR encephalitis [47]. Several others viruses have been found to potentially trigger anti-NMDAR, such as VZV [48], JEV [49], Epstein-Barr virus (EBV) [50], or measles virus [51]. Additionally, two cases of possible association between human immunodeficiency virus (HIV) infection (HIV CSF escape) and anti-NMDAR encephalitis have been published [52].

Following the emergence of studies on cases of SARS-CoV-2 infection with anti-NMDAR encephalitis during the pandemic, researchers have suggested a few possible mechanisms responsible for this association. Firstly, during COVID-19 infection, inflammatory markers and vascular permeability increase, leading to BBB disruption and a higher risk of NMDAR antibodies penetration to the CNS [24, 53].

Secondly, mimicry of non-structural proteins of SARS-CoV-2 with NMDA receptor subunit epitopes may cause an autoimmune response [24]. Thirdly, common micro-ribonucleic acid (miRNA) biomarkers of COVID-19 and anti-NMDA receptors may explain the relationship between COVID-19 and anti-NMDAR encephalitis. However, the amount of common miRNA biomarkers is low, which also explains the relatively low risk of this association [54].

The group of patients in this study was compared with Titulaer et al.'s cohort study published in February 2013 [19]. It was a multi-institutional observational study carried out during 2007-2012 on 577 patients (1-85

years) with confirmed anti-NMDAR encephalitis [19]. Demographic, clinical, and diagnostic features, treatment, and long-term outcomes were analyzed. The patient group in the current study was slightly younger (median age: 19.5 vs. 21 years) with fewer women (62.5% vs. 81%), which could explain the higher COVID-19-associated complications in the male population.

The clinical course and treatment were rather comparable in both groups. In this study, psychiatric symptoms were mostly found in adults (56%), and neurological manifestations were predominant in the pediatric group, which was comparable to the quoted study [19].

In the present study, movement disorders occurred in 62.5% (vs. 75%) of adults and 71% (vs. 95%) of children, and 69% of patients had seizures (vs. 70%). Abnormalities in brain MRI, EEG, and CSF were detected in 25, 69, and 44% of patients, respectively, compared to 33, 90, and 79% in Titulaer et al.'s cohort, respectively [19]. All patients received recommended first-line immunotherapy (IVIM, IVIG, or plasma exchange). Also, 31% received second-line immunotherapy (rituximab, azathioprine, and cyclophosphamide), which is higher than that reported in Titulaer's study (27%) [19]. In this review, nine patients (56%) recovered or substantially improved, which is lower than that reported in Titulaer's study (81%) [19]. Perhaps, there is a resemblance in the pathology of anti-NMDAR encephalitis triggered by HSV and SARS-CoV-2, as the outcomes of both are worrisome. On the other hand, the extensive statistical analysis done by Titulaer involved a median follow-up of 24 months. The short clinical observation time after AE development in the present study group may be insufficient to predict the outcomes of anti-NMDAR encephalitis during COVID-19. In this review, the severity of COVID-19 did not appear to impact the

outcome of anti-NMDAR encephalitis.

There are some concerns arising from our study. Three patients (no. 3, 5, 8) had ovarian teratoma, which is an established trigger of anti-NMDAR encephalitis. In these cases, COVID-19 could accelerate probable future encephalitis.

In one case (no. 2), anti-NMDAR antibodies were detected only in serum, which is less specific than in CSF^[20]. However, sudden clinical deterioration, EEG abnormalities, and improvement after immunotherapy suggest anti-NMDAR encephalitis due to COVID-19. In the last case (no. 16), in addition to anti-NMDAR antibodies, anti-GAD 65/67 antibodies were also detected in CSF. Syndromes associated with anti-GAD antibodies are: stiff-person syndrome, cerebellar ataxia, chronic epilepsy, and limbic encephalitis^[55]. Some articles have reported cases of anti-GAD encephalitis during COVID-19^[56, 57]. However, the dominant psychiatric symptoms of patient no. 16 were more similar to those of anti-NMDAR encephalitis.

Patient no. 3 received the third dose of BNT162b2 vaccination against SARS-CoV-2 four months before the onset of encephalitis. Some vaccines may increase the risk of anti-NMDAR encephalitis, especially vaccines against human papillomavirus (HPV), diphtheria/pertussis/tetanus/poliomyelitis (DTP-polio), VZV, influenza, yellow fever, and Japanese encephalitis^[22, 58]. Martin et al. (2022) reported a more severe course of anti-NMDARE after vaccinations compared with encephalitis without a causative agent^[58]. Cases of autoimmune encephalitis after SARS-CoV-2 vaccination have been reported in some studies^[59-61] as well as in VigiBase, the WHO Global Individual Case Safety Report (ICSR) database^[58, 61]. In the VigiBase database on December 31, 2021, there were four cases (all adults; one died) with anti-NMDARE that developed after the COVID-19 vaccine (all mRNA vaccines)^{[58,}

^{61]}. Some studies have described cases with generally favourable outcomes regardless of the type of SARS-CoV-2 vaccine^[59, 60]. The onset of anti-NMDAR encephalitis after SARS-CoV-2 vaccination has been reported to vary from 2 to 98 days^[61]. In one case (no. 3), vaccination was administered approximately 120 days before the onset of AE symptoms, which seems too late compared with encephalitis case occurring 3 days after SARS-CoV-2 infection.

There are some notable limitations in this study.

Firstly, we could only present published reports, which may likely underestimate the true incidence rate of anti-NMDAR encephalitis secondary to COVID-19. Secondly, incomplete data in some reports, coupled with inconsistency in SARS-CoV-2 diagnostic methods may lead to detection bias.

Thirdly, despite the large number of studies due to COVID-19, only a small number of anti-NMDAR encephalitis cases were reported with positive auto-antibodies as a possible consequence of SARS-CoV-2 infection.

Considering the enormity of the SARS-CoV-2 pandemic (over 700 million recorded cases to date), the possibility of co-occurrence of both diseases in analogous periods could not be ruled out.

Nevertheless, considering the possible inflammation-mediated autoimmune-associated mechanism during SARS-CoV-2 infection, and the association with other autoimmune encephalitis in the medical literature, it could be assumed that anti-NMDAR encephalitis may be caused by SARS-CoV-2. Moreover, the occurrence of anti-NMDAR encephalitis alone is rare.

It is hoped that in the future, a more detailed analysis of a larger group of patients will determine whether the association of anti-NMDAR encephalitis with SARS-CoV-2 is coincidental, or it is a possible consequence of COVID-19.

Conclusion

Anti-NMDA receptor encephalitis during SARS-CoV-2 infection is very rare. The disease should be considered in patients with COVID-19 (or a recent history of COVID-19), who exhibit sudden neuropsychiatric symptoms and seizures.

This approach should lead to further diagnostic paths, like brain MRI, EEG, CSF analysis, and detection of auto-antibodies (IgG antibodies against the NMDA receptor), followed by a search for tumour. Differential diagnosis should concern other types of autoimmune or viral encephalitis, psychosis, cerebrovascular diseases, hypoxic damage, and encephalopathy due to COVID-19. Correct early diagnosis facilitates the rapid initiation of guideline-based immunotherapy, thus ensuring a better prognosis.

Further observations are required to assess the connection between SARS-CoV-2 and anti-NMDAR encephalitis and to assess clinical prognosis and relapse statistics, especially considering the probability of worse outcomes when encephalitis is triggered by SARS-CoV-2.

Acknowledgments

The authors would like to thank Stanley Iyadurai, PhD from Johns Hopkins All Children's Hospital, and Matthew La Fontaine for proofreading.

Ethical permissions: Not required.

Authors' contributions: Justyna Jachman-Kapułka: study conceptualization and design, investigation, resources, writing, original draft preparation; Marta Rorat: conceptualization, writing, reviewing, editing, supervision. All authors read and approved the published version of the manuscript.

Conflicts of interest: The authors declare no conflict of interest.

Funding: None declared by authors.

Consent to participate: Not required.

References

1. Mao L, Jin H, Wang M, Hu Y, Chen S, He Q, et al. Neurologic manifestations of hospitalized patients with coronavirus disease 2019 in Wuhan, China. *JAMA Neurol.* 2020;77(6):683-90.
2. Studart-Neto A, Guedes BF, Tuma RL, Camelo Filho AE, Kubota GT, Iepsen BD, et al. Neurological consultations and diagnoses in a large, dedicated COVID-19 university hospital. *Arq Neuropsiquiatr.* 2020;78(8):494-500.
3. Misra S, Kolappa K, Prasad M, Radhakrishnan D, Thakur KT, Solomon T, et al. Frequency of neurologic manifestations in COVID-19: A systematic review and meta-analysis. *Neurology.* 2021;97(23):e2269-81.
4. Broła W, Wilski M. Neurological consequences of COVID-19. *Pharmacol Rep.* 6(74;2022):22-1208.
5. Ellul MA, Benjamin L, Singh B, Lant S, Michael BD, Easton A, et al. Neurological associations of COVID-19. *Lancet Neurol.* 2020;19(9):767-83.
6. Wu Y, Xu X, Chen Z, Duan J, Hashimoto K, Yan L, et al. Nervous system involvement after infection with COVID-19 and other coronaviruses. *Brain Behav Immun.* 2020;87:18-22.
7. Baig AM, Khaleeq A, Ali U, Syeda H. Evidence of the COVID-19 virus targeting the CNS: Tissue distribution, host-virus interaction, and proposed neurotropic mechanisms. *ACS Chem Neurosci.* 2020;11(7):995-8.
8. Yassin A, Nawaiseh M, Shaban A, Alsherbini K, El-Salem K, Soudah O, et al. Neurological manifestations and complications of coronavirus disease 2019 (COVID-19): A systematic review and meta-analysis. *BMC Neurol.* 2021;21:1-7.
9. Harapan BN, Yoo HJ. Neurological symptoms, manifestations, and complications associated with severe acute respiratory syndrome coronavirus 2 (SARS-CoV-2) and coronavirus disease 19 (COVID-19). *J Neurol.* 2021;268(9):3059-71.
10. Nabizadeh F, Balabandian M, Sodeifian F, Rezaei N, Rostami MR, Moghadasi AN. Autoimmune encephalitis associated with COVID-19: A systematic review. *Mult Scler Relat Dis.* 2022;62:103795.
11. Guedes BF. NeuroCOVID-19: A critical review. *Arq Neuro Psiquiatr.* 2022;80(5 Suppl 1):281-9.
12. Pinzona RT, Wijayaa VO, Jodya AA, Nunsioa PN, Buana RB. Persistent neurological manifestations in long COVID-19 syndrome: A systematic review and meta-analysis. *J Infect Public Health.* 2022;15(8):856-69.

13. Xue H, Zeng L, He X, Xu D, Ren K. Autoimmune encephalitis in COVID-19 patients: A systematic review of case reports and case series. *Front Neurol.* 2023;14:1207883.
14. Stoian A, Stoian M, Bajko Z, Maier S, Andone S, Cioflinc RA, et al. Autoimmune encephalitis in COVID-19 infection: Our experience and systematic review of the literature. *Biomedicines.* 2022;10(4):774.
15. Islam MA, Cavestro C, Alam SS, Kundu S, Kamal MA, Reza F. Encephalitis in patients with COVID-19: A systematic evidence-based analysis. *Cells.* 2022;11(16):2575.
16. Dalmau J, Graus F. Antibody-mediated encephalitis. *N Engl J Med.* 2018;378(9):840-51.
17. Kayser MS, Dalmau J. Anti-NMDA receptor encephalitis, autoimmunity, and psychosis. *Schizophr Res.* 2016;176(1):36-40.
18. Miya K, Takahashi Y, Mori H. Anti-NMDAR autoimmune encephalitis. *Brain Dev.* 2014;36(8):645-52.
19. Titulaer MJ, McCracken L, Gabilondo I, Armangué T, Glaser C, Iizuka T, et al. Treatment and prognostic factors for long-term outcome in patients with anti-N-methyl-D-aspartate (NMDA) receptor encephalitis: A cohort study. *Lancet Neurol.* 2013;12(2):157-65.
20. Dalmau J, Armangué T, Planagumà J, Radošević M, Mannara F, Leypoldt F, et al. An update on anti-NMDA receptor encephalitis for neurologists and psychiatrists: Mechanisms and models. *Lancet Neurol.* 2019;18(11):1045-57.
21. Graus F, Titulaer MJ, Balu R, Benseler S, Bien CG, Cellucci T, et al. A clinical approach to diagnosis of autoimmune encephalitis. *Lancet Neurol.* 2016;15(4):391-404.
22. Wang H. Anti-NMDA receptor encephalitis and vaccination. *Int J Mol Sci.* 2017;18(1):193.
23. Schabitz WR, Rogalewski A, Hagemisteir C, Bien CG. VZV brainstem encephalitis triggers NMDA receptor immunoreaction. *Neurology.* 2014;83(24):2309-11.
24. Vasilevska V, Guest PC, Bernstein HG, Schroeter ML, Geis C, Steiner J. Molecular mimicry of NMDA receptors may contribute to neuropsychiatric symptoms in severe COVID-19 cases. *J Neuroinflammation.* 2021;18(1):1-8.
25. McHattie AW, Coebergh J, Khan F, Morgante F. Palilalia as a prominent feature of anti-NMDA receptor encephalitis in a woman with COVID-19. *J Neurol.* 2021;268(11):3995-7.
26. Mukherjee J, Goyal S, Arshad F, Nashi S, Srijithesh PR, Kulkarni GB, et al. Co-occurrence of anti-N-methyl-D-aspartate receptor encephalitis and COVID-19 infection: Case series of two patients with a brief review of literature. *Asian J Med Sci.* 2022;13(8):245-9.
27. Lee H, Jeon JH, Choi H, Koh SH, Lee KY, Lee YJ, et al. Anti-N-methyl-D-aspartate receptor encephalitis after coronavirus disease 2019. A case report and literature review. *Medicine.* 2022;101(35):e30464.
28. Allahyari F, Hosseinzadeh R, Nejad JH, Heiat M, Ranjbar R. A case report of simultaneous autoimmune and COVID-19 encephalitis. *J Neurovirol.* 2021;27(3):504-6.
29. Alvarez Bravo G, Ramio IT. Anti-NMDA receptor encephalitis secondary to SARS-CoV-2 infection. *Neurologia.* 2020;35(9):699-700.
30. Alvi JR, Sultan MH, Sultan T. Post COVID anti-NMDAR encephalitis in an adolescent girl. *Pak J Neurol Sci.* 2022;17(1):16-20.
31. Burr T, Barton C, Doll E, Lakhota A, Sweeney M. N-methyl-d-aspartate receptor encephalitis associated with COVID-19 infection in a toddler. *Pediatr Neurol.* 2021;114:75-6.
32. Derakhshani F, Ghazavi M, Hosseini N. Autoimmune encephalitis due to COVID-19 in a young patient. *Iran J Child Neurol.* 2023;17(2):135-42.
33. Kaur P, MV V, Madarkar BS. Infantile anti-N-methyl-D-aspartate receptor encephalitis post-SARS-CoV-2 infection. *Indian Pediatr.* 2022;59(4):343-4.
34. Monti G, Giovannini G, Marudi A, Bedin R, Melegari A, Simone AM, et al. Anti-NMDA receptor encephalitis presenting as new onset refractory status epilepticus in COVID-19. *Seizure.* 2020;81:18-20.
35. Panariello A, Bassetti R, Radice A, Rossotti R, Puoti M, Corradin M, et al. Anti-NMDA receptor encephalitis in a psychiatric Covid-19 patient: A case report. *Brain Behav Immun.* 2020;87:179-81.
36. Saini L, Krishna D, Tiwari S, Goyal JP, Kumar P, Khara D, et al. Post-COVID-19 immune-mediated neurological complications in children: An ambispective study. *Pediatr Neurol.* 2022;136:20-7.
37. Sanchez-Larsen A, Rojas-Bartolomé L, Fernández-Valiente M, Sopelana D. Anti-NMDA-R encephalitis post-COVID-19: Case report and proposed physiopathologic mechanism. *Neurologia.* 2023;38(7):513-6.
38. Sanchez-Morales AE, Urrutia-Orsorio M, Camacho-Mendoza E, RosalesPedraza G, Davila-Maldonado L, Gonzalez-Duarte A, et al. Neurological manifestations temporally associated with SARS-CoV-2 infection in pediatric patients in Mexico. *Childs Nerv Syst.* 2021;37(7):2305-12.

39. Sarigecili E, Arslan I, Ucar HK, Celik U. Pediatric anti-NMDA receptor encephalitis associated with COVID-19. *Childs Nerv Syst.* 2021;37(12):3919-22.
40. Valadez-Calderon J, Navarro AO, Rodriguez-Chavez E, Vera-Lastra O. Co-expression of anti-NMDAR and anti-GAD65 antibodies. A case of autoimmune encephalitis in a post-COVID-19 patient. *Neurologia.* 2022;37(6):503-4.
41. Joubert B, Dalmau J. The role of infections in autoimmune encephalitis. *Rev Neurol.* 2019;175(7-8):420-6.
42. Swayne A, Warren N, Prain K, Gillis D, Wong R, Blum S. Analysing triggers for anti-NMDA-receptor encephalitis including herpes simplex virus encephalitis and ovarian teratoma: Results from the Queensland Autoimmune Encephalitis cohort. *Intern Med J.* 2021;52(11):1943-9.
43. Armangue T, Leypoldt F, Málaga I, Raspall-Chaure M, Marti I, Nichter C, et al. Herpes simplex virus encephalitis is a trigger of brain autoimmunity. *Ann Neurol.* 2014;75(2):317-23.
44. Armangue T, Spatola M, Vlaga A, Mattozzi S, Cárceles-Cordon M, Martinez-Heras E, et al. Frequency, symptoms, risk factors, and outcomes of autoimmune encephalitis after herpes simplex encephalitis: A prospective observational study and retrospective analysis. *Lancet Neurol.* 2018;17(9):760-72.
45. Mohammad SS, Sinclair K, Pillai S, Merheb V, Aumann TD, Gill D, et al. Herpes simplex encephalitis relapse with chorea is associated with autoantibodies to N-methyl-d-aspartate receptor or dopamine-2 receptor. *Mov Disord.* 2014;29(1):117-22.
46. Leypoldt F, Titulaer MJ, Aguilar E, Walther J, Bönstrup M, Havemeister S, et al. Herpes simplex virus-1 encephalitis can trigger anti-NMDA receptor encephalitis: Case report. *Neurology.* 2013;81(18):1637-9.
47. Salovin A, Glanzman J, Roslin K, Armangue T, Lynch DR, Panzer JA. Anti-NMDA receptor encephalitis and nonencephalitic HSV-1 infection. *Neurol Neuroimmunol Neuroinflamm.* 2018;5(4):e458.
48. Schäbitz WR, Rogalewski A, Hagemeister C, Bien C. VZV brainstem encephalitis triggers NMDA receptor immunoreaction. *Neurology.* 2014;83(24):2309-11.
49. Ma J, Zhang T, Jiang L. Japanese encephalitis can trigger anti-N-methyl-D-aspartate receptor encephalitis. *J Neurol.* 2017;264:1127-31.
50. Xu CL, Liu L, Zhao WQ, Li JM, Wang RJ, Wang SH, et al. Anti-N-methyl-D-aspartate receptor encephalitis with serum anti-thyroid antibodies and IgM antibodies against Epstein-Barr virus viral capsid antigen: A case report and one year follow-up. *BMC Neurol.* 2011;11:1-7.
51. Ioannidis P, Papadopoulos G, Koufou E, Parrisis D, Karacostas D. Anti-NMDA receptor encephalitis possibly triggered by measles virus. *Neurol Belg.* 2015;115:801-2.
52. Moloney PB, Hutchinson S, Heskin J, Mulcahy F, Langan Y, Conlon NP, et al. Possible N-methyl-D-aspartate receptor antibody-mediated encephalitis in the setting of HIV cerebrospinal fluid escape. *J Neurol.* 2020;267(5):1348-52.
53. Pacheco-Herrero M, Soto-Rojas LO, Harrington CR, Flores-Martinez YM, Villegas-Rojas MM, León-Aguilar AM, et al. Elucidating the neuropathologic mechanisms of SARS-CoV-2 infection. *Front Neurol.* 2021;12:660087.
54. Wang H. COVID-19, anti-NMDA receptor encephalitis, and microRNA. *Front Immunol.* 2022;13:825103.
55. Muñoz-Lopetegi A, de Bruijn MA, Boukhrissi S, Bastiaansen AE, Nagtzaam MM. Neurologic syndromes related to anti-GAD65. Clinical and serologic response to treatment. *Neurol Neuroimmunol Neuroinflamm.* 2020;7(3):e696.
56. Emekli AS, Parlak A, Göcen NY, Kürtüncü M. Anti-GAD associated post-infectious cerebellitis after COVID-19 infection. *Neurol Sci.* 2021;42:3995-4002.
57. Salari M, Harofteh ZB, Etemadifar M. Autoimmune meningoencephalitis associated with anti-glutamic acid decarboxylase antibody following COVID-19 infection: A case report. *Clin Case Rep.* 2022;10(12):e6597.
58. Martin S, Azzouz B, Morel A, Trenque T. Anti-NMDA receptor encephalitis and vaccination: A disproportionality analysis. *Front Pharmacol.* 2022;13:940780.
59. Flannery P, Yang I, Keyvani M, Sakoulas G. Acute psychosis due to anti-N-methyl D-aspartate receptor encephalitis following COVID-19 vaccination: A case report. *Front Neurol.* 2021;12:764197.
60. Abdelhady M, Husain MA, Hawas Y, Elazb MA, Mansour LS, Mohamed M, et al. Encephalitis following COVID-19 vaccination: A systematic review. *Vaccines.* 2023;11(3):576.
61. Martin S, Azzouz B, Morel A, Tralongo F, Dorguin G, Trenque T. Anti-NMDA receptor encephalitis and COVID-19 vaccination? *Fundam Clin Pharmacol.* 2022;36:99