

Chronic Trichomoniasis in a Woman with Mixed Vaginitis Infection in Bandar Abbas, Iran: A Case Report

ARTICLE INFO

Article Type Case report

Authors

Maryam Ghobahi, MSc¹
Maryam Arfaatabar, PhD²
Mehrgan Heydari Hengami, BA¹
Sareh Bagheri-Josheghani, MSc³
Zohreh Fakhrieh-Kashan, PhD^{4*}

How to cite this article

Ghobahi M., Arfaatabar M., Heydari Hengami M., Bagheri-Josheghani S., Fakhrieh-Kashan Z. Chronic Trichomoniasis in a Woman with Mixed Vaginitis Infection in Bandar Abbas, Iran: A Case Report. Infection Epidemiology and Microbiology. 2020;6(4): 305-309

¹Infectious and Tropical Diseases Research Center, Hormozgan University of Medical Sciences, Bandar Abbas, Iran.

²Department of Medical Laboratory Sciences, Kashan Branch, Islamic Azad University, Kashan, Iran.

³Kashan University of Medical Sciences, Kashan, Iran

⁴Department of Medical Parasitology and Mycology, School of Public Health, Tehran University of Medical Sciences, Tehran, Iran.

* Correspondence

Address: Department of Medical Parasitology and Mycology, School of Public Health, Tehran University of Medical Sciences, Tehran, Iran
zfk579@gmail.com

Article History

Received: July 05, 2020

Accepted: September 15, 2020

Published: November 19, 2020

ABSTRACT

Background: *Trichomonas vaginalis* is, one of due to vaginitis, the most common non-viral sexually transmitted and treatable infection in the world. Co- infection of *T. vaginalis* along with other agents of vaginitis should always be considered in patients with chronic vulvovaginal symptoms.

Case: An Iranian woman with 32 years of age and signs of vaginitis infection referred to a midwifery clinic in Bandar Abbas. While she used antifungal and antibacterial medications many times during the past two years to treat her vaginitis infection, but since her husband did not do so, all the clinical signs of her infection reappeared again after a short time. A miscarriage, genital warts in the lower end of the uterus (cervix), yellowish-green foamy secretion, and vigorous redness of the lower end of the uterus were among the problems reported in her medical record. To diagnose the disease, sampling was done from the posterior fornix of vagina and using direct smear and Diamond culture medium, the specimen was examined for the presence of *T. vaginalis* by a specialist in parasitology. Based on the direct smear test results, the specimen was positive for yeast and bacteria and negative for *T. vaginalis*, while culture test result was positive for the presence of *T. vaginalis*. Therefore, the woman referred to a physician qualified in gynecology for her infection therapy, but this time with her husband. The duration of their treatment was three months, after which the culture test result (after 72 h) was negative for *T. vaginalis*, and the clinical signs of the infection ameliorated.

Conclusion: It is recommended that, in addition to careful examination of patients' clinical symptoms, direct smear and culture methods be employed in midwifery centers to correctly diagnose vaginitis. In addition, the treatment of sexually transmitted diseases (STD) in people involved in a sexual relationship should be done simultaneously.

Keywords: Chronic, *Trichomonas vaginalis*, Bandar Abbas.

CITATION LINKS

[1] Simões-Barbosa A, Feijó GC, Silva JXd, Leal IIR, Barbosa TWP. A six-year follow-up survey of sexually transmitted diseases in Brasilia, the capital... [2] Karabulut A, Alan T, Ekiz MA, İritiş A, Kesen Z, Yahşi S. Evaluation of cervical screening results in a population at normal risk. Inter J of... [3] Nijhawan AE, Chapin KC, Salloway R, Andrea S, Champion J, Roberts M, et al. Prevalence and predictors of trichomonas infection in newly... [4] F Kashan Z, Arbabi M, Delavari M, Hooshyar H, Taghizadeh M, Joneydy Z. Effect of Verbascum thapsus Ethanol... [5] Ka Sena AC, Miller WC, Hobbs MM, Schwabke JR, Leone PA, Swygard H, et al. Trichomonas vaginalis infection in male sexual partners: implications for diagnosis, treatment, and prevention. Clinical infectious diseases. 2007;13-22. [6] Ryu J-S, Min D-Y. Trichomonas vaginalis and trichomoniasis in the Republic of Korea. The Korean journal of parasitology. 2006; 44(2):101. [7] Poole DN, McClelland RS. Global epidemiology of Trichomonas vaginalis. Sex Transm Infect. 2013; 89(6):418-22. [8] Ali V, Nozaki T. Current therapeutics, their problems, and sulfur-containing-amino-acid metabolism as a novel target against infections by "amitochondriate" protozoan parasites. Clini micro rev. 2007; 20(1):164-87. [9] Arbabi M, Delavari M, Fakhrieh-Kashan Z, Hooshyar H. Review of Trichomonas vaginalis in Iran, based on epidemiological situation. J of repro & infer. 2018; 19(2):82. [10] Ghobahi M, Hamed Y, Shamseddin J, Heydari-Hengami M, Sharifi-Sarasiabi K. Frequency of Trichomoniasis and Related Risk Factors in the Women Referred to Bandar Abbas Health Centers, Iran, 2017-2018. Hormo Med J. 2019; 23(1):e88906. [11] Habibi A, Nateghi Rostami M, Douraghi M, Dolati M, Rashidi BH, Ahangari R. Frequency of genital infection with Trichomonas vaginalis in women referred to gynecology hospital of the city of Qom. J of Dermato and Cos. 2016; 6(4):190-9. [12] Kissinger P. Trichomonas vaginalis: a review of epidemiologic, clinical and treatment issues. BMC infec dis. 2015; 15(1):307.

Introduction

Vaginitis as a vaginal inflammation is one of the most prevalent infectious diseases among patients referring to midwifery clinics. Bacterial vaginosis, candidiasis, and trichomoniasis are the main leading causes of vaginitis [1]. Bacterial vaginosis is the most common cause of vaginal infection, and the second most common form of vaginal infection among people is vaginal candidiasis [1, 2]. Another important cause of vaginal infection accounting for 20-25 % of vaginitis is trichomoniasis, which is caused by *Trichomonas vaginalis* and also play an important role in disseminating human immunodeficiency virus (HIV) infection [3]. The simultaneous presence of at least two vaginal pathogens could be described as mixed vaginitis. It has been estimated that approximately 250 million trichomoniasis cases are diagnosed worldwide annually [4]. While trichomoniasis is asymptomatic in 85% of infected women, some of its symptoms include: yellowish-green foamy secretion, painful urination, pruritus, redness and pain in the genitals, cervical hemorrhage, dyspareunia, and rupture of the fetal membranes. Infection in men is usually asymptomatic; in fact, they play the role of the parasite carriers [5]. Trichomoniasis is more common among women with the age ranges from 16 to 53 years [6].

Detection of *T. vaginalis* based on clinical symptoms is low sensitive due to the similarity between the symptoms of *T. vaginalis* and other causes of vaginitis, [4]. Therefore, in order to correctly diagnose *T. vaginalis*, it is necessary to use one or two parasite detection methods such as wet mount technique (the most common low-sensitivity diagnostic method), culture methods (with higher sensitivity than wet mount), and molecular approaches which are the most sensitive and specific methods with low cost and applicability in

conventional diagnostic laboratory tests [7]. Metronidazole is the drug of choice and the most widely used drug for vaginitis therapy in both sexual partners; simultaneous treatment of both sexual partners is recommended and necessary [8].

In this study, a chronic trichomoniasis case was reported in a woman with mixed vaginitis infection caused by vulvovaginal candidiasis and bacterial vaginosis (diagnosed by culture) and genital warts in her cervix.

Case report

A 32-year-old Iranian woman whose main occupation was housekeeping with signs of vaginitis infection referred to a midwifery clinic in Bandar Abbas in 2019. She was married for two years. During the past two years since her marriage, she was referred to midwifery clinics many times due to vaginal problems such as uterine hemorrhage and dyspareunia. While she received 150 mg clindamycin capsule, 1% clotrimazole cream, and triple sulfa vaginal to treat her infection, but since her husband did not do so; all the clinical signs reappeared again after a short time. She had a spontaneous miscarriage six months ago. Among her clinical symptoms were genital warts in the lower end of the uterus (cervix), yellowish-green foamy secretion, uterine hemorrhage, dyspareunia, and vigorous redness in the lower end of the uterus. To diagnose the disease, sampling was done from the posterior fornix of vagina and using direct smear and Diamond medium, the specimen was examined for the presence of *T. vaginalis* by a specialist in parasitology. Vaginal pH was > 5.5. The wet mount and Giemsa-stained direct smear tests results were positive for yeast (many) and bacteria (moderate) and negative for *T. vaginalis*. Culture medium was incubated at 37° C and investigated every 12 h for 3 days, the result of which was positive for *T. vaginalis* after 24 hours (Figure 1, 2). Therefore, the

woman referred to a physician qualified in gynecology for her infection therapy, but this time with her husband. They received 150 mg fluconazole capsule for 3 days, metronidazole vaginal for 2 weeks, 300 mg clindamycin capsule for 3 weeks, and 5% acclovir cream. The duration of their treatment was three months, after which the patient referred to the clinic for vaginal resampling. Direct smear (examined immediately after sampling) and culture (examined after 72 hours) tests results were negative for the presence of *T. vaginalis* (trichomoniasis), and her clinical symptoms ameliorated.

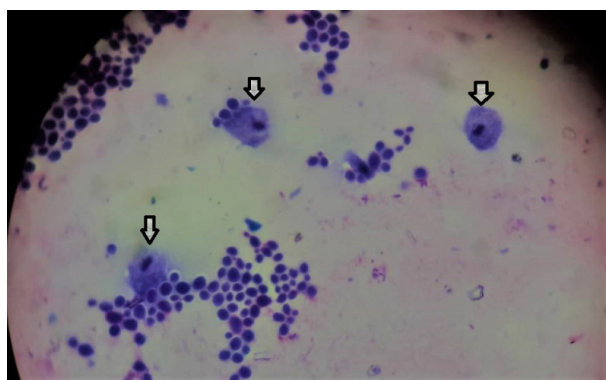


Figure 1) Giemsa- staining of *Trichomonas vaginalis* from Diamond medium after 24 hours of incubation at 37 ° C. x400

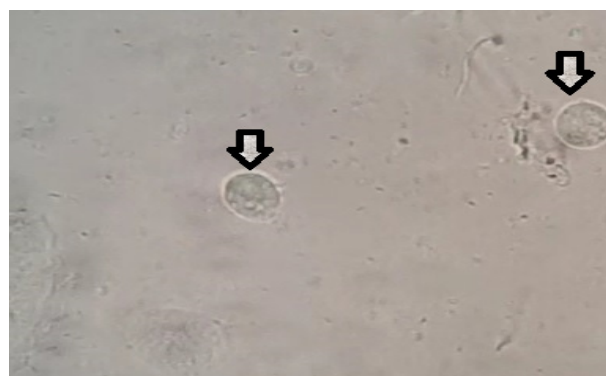

Figure 2) Wet smear containing *Trichomonas vaginalis* from Diamond medium after 72 hours of incubation at 37 ° C. x400

Discussion

Trichomoniasis is one of the most prevalent infectious diseases transmitted through sexual contact. *T. vaginalis* is a flagellated protozoan parasite and the causative agent

of trichomoniasis, infecting the urogenital tract of human and exerting mechanical stress on host cells (2 and 7). Recently, due to the major contribution of *T. vaginalis* infection to the transmission of HIV infection to men and women, patients with chronic trichomoniasis have received much attention as a major public health concern. The relationship between these two infections is bidirectional so that *T. vaginalis* infection increases the risk of HIV transmission, and vice versa [3]. The prevalence rate of *T. vaginalis* is different in other geographical regions of Iran, depending on the type of communities, cultures, and religions. It varies from 0.4 to 42% [9]. In a recent study, the prevalence rate of trichomoniasis among infected women referring to the health centers of Bandar Abbas was reported to be 2.6% [10]. The patient in this study had a history of miscarriage, which was similar to the studies by Ghobahi et al. (2019) in Bandar Abbas [10] and Habibi et al. (2016) in Qom (11). This patient was co-infected by candidiasis, bacteria, trichomoniasis, and herpes virus, which probably cause changes in the vagina flora by sexually transmitted diseases (STDs) that could augment the risk of miscarriage [10]; however, further research is needed to confirm the effect of trichomoniasis on the increased risk of miscarriage.

Due to the similarity between the signs and symptoms of various type of vaginitis, it is not possible to rely solely on clinical symptoms to correctly diagnose trichomoniasis [4]. The patient under study was treated for two years only based on clinical symptoms with medications that were suitable for other vaginitis causative agents, which were not effective. The use of molecular methods, as the most sensitive and specific method, is not common in the lab [7]. Therefore, the simultaneous use of both wet smear method, as the most cost-effective and fastest method,

and culture method, as the standard and more sensitive method, could lead to the rapid diagnosis of vaginitis causative agents, allowing patient to start the treatment faster and safer [7, 10]. In this study, the wet smear test result was negative but the culture method was positive for *T. vaginalis*.

Food and Drug Administration (FDA)-approved 5'-nitroimidazole is the only efficient drug commonly used for trichomoniasis therapy [5]. Infection in men is often without clinical symptoms, and they actually play the role of the parasite carriers for women. Therefore, simultaneous treatment of both sexual partners (female and male) is recommended and necessary [1, 5]. In this study, after the correct diagnosis of the disease, the patient under study and her husband were treated at the same time, causing the symptoms to be ameliorated. The World Health Organization (WHO) has estimated that approximately half of all sexually disseminated infections could be treated through accurate and timely diagnosis of trichomoniasis [12].

Conclusion

Trichomoniasis infection may create a milieu that favors the growth of other causative agents of vaginitis; therefore, it is not possible to diagnose a mixed infection caused by *T. vaginalis* and other vaginitis causative agents based on clinical symptoms. Thus, accurate diagnosis of vaginitis causative agents by sensitive and specific methods is a key point for timely treatment, reduction of transmission risk, and prevention of negative health outcomes. Ultimately, simultaneous treatment of sexual partners could have an important impact on the control of STDs.

Acknowledgments: The authors would like to thank Hormozgan University of Medical Sciences for supporting and funding this study and all those who contributed to this

work, especially Mrs Soheila moradi for her assistance in sampling. They also thank the patient for her efficient collaborations.

Ethical Permissions: No ethical permission was stated by the authors.

Conflicts of Interests: The authors declared no competing interest.

Authors' Contribution: Conceptualization: MG, MA, MHH, SBJ, ZFK; Data curation and formal analysis: MG, MA, MHH, SBJ, ZFK; Investigation: MG, MA, MHH, SBJ, ZFK; Methodology and project administration: MG, MA, MHH, SBJ, ZFK; Supervision: ZFK; Validation: ZFK; Writing of original draft: MG, MA, MHH, SBJ, ZFK; Writing, reviewing, and editing: MG, MA, MHH, SBJ, ZFK:

Fundings: This study was supported by , Hormozgan University of Medical Sciences, Bandar Abbass, Iran.

Consent to participate:Consent form was obtained from patient.

Reference

1. Simões-Barbosa A, Feijó GC, Silva JXd, Leal IIR, Barbosa TWP. A six-year follow-up survey of sexually transmitted diseases in Brasilia, the capital of Brazil. Br J of Infec Dis. 2002; 6(3): 110-7.
2. Karabulut A, Alan T, Ekiz MA, İritaş A, Kesen Z, Yahşi S. Evaluation of cervical screening results in a population at normal risk. Inter J of Gyneco & Obste. 2010; 110(1):40-2.
3. Nijhawan AE, Chapin KC, Salloway R, Andrea S, Champion J, Roberts M, et al. Prevalence and predictors of trichomonas infection in newly incarcerated women. Sex trans dis. 2012; 39(12).
4. F Kashan Z, Arbabi M, Delavari M, Hooshyar H, Taghizadeh M, Joneydy Z. Effect of Verbascum thapsus Ethanol Extract on Induction of Apoptosis in Trichomonas vaginalis in vitro. Infec Dis -Drug Target. 2015; 15(2):125-30.
5. Ka Sena AC, Miller WC, Hobbs MM,

- Schwebke JR, Leone PA, Swygard H, et al. *Trichomonas vaginalis* infection in male sexual partners: implications for diagnosis, treatment, and prevention. *Clinical infectious diseases*. 2007;13-22.
6. Ryu J-S, Min D-Y. *Trichomonas vaginalis* and trichomoniasis in the Republic of Korea. *The Korean journal of parasitology*. 2006; 44(2):101.
 7. Poole DN, McClelland RS. Global epidemiology of *Trichomonas vaginalis*. *Sex Transm Infect*. 2013; 89(6):418-22.
 8. Ali V, Nozaki T. Current therapeutics, their problems, and sulfur-containing-amino-acid metabolism as a novel target against infections by "amitochondriate" protozoan parasites. *Clini micro rev*. 2007; 20(1):164-87.
 9. Arbabi M, Delavari M, Fakhrieh-Kashan Z, Hooshyar H. Review of *Trichomonas vaginalis* in Iran, based on epidemiological situation. *J of repro & infer*. 2018; 19(2):82.
 10. Ghobahi M, Hamed Y, Shamseddin J, Heydari-Hengami M, Sharifi-Sarasiabi K. Frequency of Trichomoniasis and Related Risk Factors in the Women Referred to Bandar Abbas Health Centers, Iran, 2017-2018. *Hormo Med J*. 2019; 23(1):e88906.
 11. Habibi A, Nateghi Rostami M, Douraghi M, Dolati M, Rashidi BH, Ahangari R. Frequency of genital infection with *Trichomonas vaginalis* in women referred to gynecology hospital of the city of Qom. *J of Dermato and Cos*. 2016; 6(4):190-9.
 12. Kissinger P. *Trichomonas vaginalis*: a review of epidemiologic, clinical and treatment issues. *BMC infec dis*. 2015; 15(1):307.