

Neurological Complication of Infective Endocarditis Misdiagnosing with Multiple Sclerosis: A Case Report

Davood Yadegarynia¹, Shervin Shokouhi^{1*}, Shabnam Tehrani¹, Anita Yazdani¹

¹Infectious Diseases and Tropical Medicine Research Center, Shahid Beheshti University of Medical Sciences, Tehran, IR Iran

*Corresponding author: Shervin Shokouhi, Infectious Diseases and Tropical Medicine Research Center, Shahid Beheshti University of Medical Sciences, Tehran, IR Iran, , shsh.50@gmail.com, Tel: +982122439963

Submitted: May27, 2017; Revised: June 24, 2017; Accepted: July 06, 2017

Abstract

Infective endocarditis (IE) is a rare but serious disease with different clinical pictures. Its neurological complication is commonly mistaken in term of diagnosis and treatment. Therefore, such cases must be taken under further diagnostic imaging for searching the basic structural lesions. Known causes of these signs include cardio embolism with hemorrhagic transformation, septic embolism, or mycotic aneurysms. In this paper, our case was a patient admitted for the evaluation of local neurological complaint reason and subsequent therapy. He was found to have bacterial endocarditis after medical workup. It was diagnosed prospectively from positive tests of vegetation on Transesophageal echocardiogram and Magnetic resonance imaging (MRI) results.

Keywords: Infective endocarditis, Septic cerebral emboli, Neurological complication.

1. Background

IE is still a challenging problem in clinical medicine with a two-to-one proportion in males and females, respectively (1). Those with degenerative valve sclerosis or prosthetic valves and patients exposed to nosocomial infections are considered as at risk population while the predisposing role of rheumatic valvulopathy has been decreased according to a recent research (2). Infective endocarditis has remained as a confronting issue in terms of clinical diagnosis and may have a wide range of initial manifestations (3). Despite advances in echocardiographic studies, advanced antibiotic regimen, and early surgical treatment, infective endocarditis continues to be an important cause of mortality among the infectious diseases (4). Therefore, its early diagnosis is critical for reducing its complications and mortality. On the other hand, IE originated from vegetation of left-sided bacterial endocarditis is disseminated to distant organs; especially to brain, spleen, and kidneys, as described in our case; and commonly presented with a mass of neurologic squeals, including encephalopathy, headache, seizures, stroke, and meningitis (5). Stroke in the setting of IE may be hemorrhagic or ischemic and is commonly secondary to cardio embolism, septic embolism, or mycotic aneurysms. in 2.7–7% of patients with IE intracranial hemorrhage is occurring which is uncommon (6). This study is a report of a cerebral embolism case with aphasia and hemiplegia due to primary IE. Further medical investigations revealed multiple cerebral infarction and mitral valve vegetation, which are signs of a rare case of cerebral septic embolism due to primary infective endocarditis.

2. Case presentation

This study is a case report of a 48 year old man admitted to Iran Mehr hospital with hemiplegia and aphasia complications. He had been hospitalized in another health care center following hemiparesis, blurred vision, nausea, vomiting, and speech problem. As reported by his family, he was complaining of vertigo and paresthesia in his both hands prior to initial hospitalization either. Multiple sclerosis had been introduced as

his final diagnosis by a neurologist in the first hospital. Thus, corticosteroid pulse therapy had been done, and patient had received 5 dose of methylprednisolone, but symptoms have kept on deteriorating. Patient's family discharged him with personal gratification and brought him to Iranmehr hospital. On admission time, the patient's Glasgow coma scale scores were 8. His vital signs were stable, and he was afebrile (BP: 120/80, PR: 80, RR: 14, T: 37). Cardiopulmonary examination seemed normal. In neurological exams, meningeal signs were negative, ruling out Meningitis. Patient's family had not provided any history of special disease, except for that he had been a smoker and used opium once in a while. Therefore, he was hospitalized in intensive care unit for a week and then discharged. Transesophageal echocardiography was done (on the 2nd day of the hospitalization) and reported moderate size (7 mm) of branching vegetation on atrial side of tip of both Mitral valve (MV) leaflets. Ejection fraction was about 60%. Pulmonary artery pressure was 25 millimeter of mercury.

On the 3rd day, brain computed tomography scan was performed and showed hypo density in the right occipital lobe of the brain and both cerebral lobes, especially in the right area, suggesting a cerebrovascular accident (CVA). Thus, MRI was requested, and patient underwent antimicrobial treatment with Meropenem, Vancomycin, and Gentamycin. Chest x-ray, abdominal pelvic and Doppler sonography results were normal.

Magnetic resonance imaging was performed on the 5th day, and extensive abnormal signal intensity was shown mostly on the right cerebral hemisphere. Diffusion weighted imaging (DWI) recommended acute infarction in parietal lobes and small scattered cortical and subcortical infarctions in posterior left parietal and left frontal lobes.

There were also a few high signal intensity foci on T1 and T2 images of the right frontal and right and left parietal subcortical regions due to hemorrhagic infarction, which can be attributed to the patient's aphasia state. In addition, there were a few lacunar infarctions in the right centrum semi-oval, which was a new finding in comparison with prior results. Patient's diagnostic images are illustrated in Figure 1.

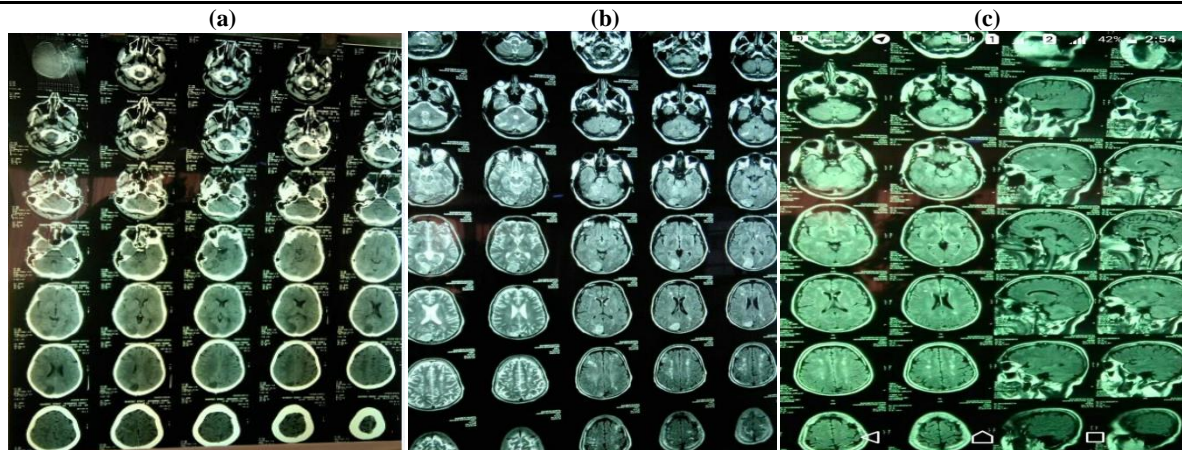


Figure 1. Patient's diagnostic images. (a) shows the primary CT scan, (b and c) show patient's MRI taken 5 days after the initiation of the symptoms.

Table 1. Preliminary lab findings.

WBC	Hg	LDH	HIV Ab	HBS Ag	HCV Ab	Anti ds DNA	C3/C4	C-ANCA	P-ANCA	ESR	CRP	UA	Anticardiolipin/Ig a/Igm	Cr	BUN
15000	14.8	400	Neg	Neg	Neg	Neg	Norm	Norm	Norm	2	27	Norm	Neg	1	30

According to the findings, we diagnosed endocarditis with multiple septic cerebral embolisms. Plavix and Dilantin were also prescribed. Preliminary lab findings are shown in Table 1.

Three weeks later, another Transesophageal echocardiography was done. Size of vegetations was reported to become much smaller (2.5 mm). Unfortunately, neurological signs had still remained.

3. Discussion

IE may be presented with primary neurological symptoms. Yanagihara et al. (2003) reported a case of *Staphylococcus aureus* endocarditis presented with fever and concurrent subdural hematoma (SDH) and subarachnoid hemorrhage (SAH) (7). In their patient, multiple abscesses were found in their patients especially on their brain imaging; however, no infarcted area was evident. In another study, a case of IE was reported with left-sided hemiplegia, which after diverse evaluations, it turned out to be cardio embolic stroke (8). the most common pathogens isolated from blood cultures in IE. are *S. aureus* and *Streptococcus viridans*. *S. aureus*, *Enterococcus*, and *Escherichia coli* carry the worst outcome related to their predisposition for multiple cerebral embolism (9). by contrast, embolism associated with streptococcal infections usually occurs later, within the second week of infection. Streptococcal endocarditis is associated with a solitary embolus and carries a slightly more favorable prognosis (6). Unfortunately, in our case, no specimen was isolated from vegetation. Blood culture was negative. Therefore, we were not aware of the type of bacterial pathogen.

The diagnostic imaging test of choice is a cerebral angiogram. In patients with known infectious endocarditis presented with new neurologic symptoms, an angiogram is indicated (10). However, the incidence of angiogram-negative hemorrhage with IE is high. In our case, we gathered data using multiple diagnostic tools and put the puzzle pieces together instead of implementing the standard tests, which might be due to the initial wrong diagnosis of multiple sclerosis, distracting

us; otherwise, we were able to identify the reality of IE sooner. This situation can be mirrored in other similar setting where the patient is put in the wrong way for clinical workup, which was our reason for introducing the case.

Prognosis in patients with neurologic complications associated with IE is based on the early antibiotic therapy likely to the degree of neurologic injury (1). Initiating earlier therapy is associated with improved outcomes [6]. In our patient, antibiotic therapy was not started at the first hospital. This may have contributed to the sinister symptoms observed in admission time. In addition, he did not have the usual embolic signs of endocarditis, including Roth spots, Osler's nodes and cardiac murmur. In summary, in respect to the patient's history and absence of prior and common cardiopulmonary complications, we faced with a case that must have been presented in order to help clinicians better understand the possible occurrence of infectious etiology in such confronting conditions.

Although the incidence of central nervous system complications in IE is still low, infectious specialist must consider the bacterial endocarditis as a cause of intracranial hemorrhage (ICH) and incorporate this issue in differential diagnosis when facing a local neurological sign.

4. Conclusion

We present a case of infectious endocarditis diagnosed through diverse investigations. In this paper, we tried to draw attentions to the different diagnosis of a set of neurological symptoms with non-cardiogenic cause as a health concern.

Conflicts of interest

None to declare.

Acknowledgements

The authors would like to acknowledge their gratitude to staffs, who participated in data collection in Iran Mehr hospital.

Authors' Contributions

All the authors contributed to all parts of the research process; including the conduction and collection of clinical and laboratory data.

Funding/Support

None declared.

References

1. Mylonakis E, Calderwood SB. Infective endocarditis in adults. *N Engl J Med*. 2001; 345(18):1318-30.
2. Murdoch DR, Corey GR, Hoen B, Mira JM, Fowler VG, Bayer AS, et al. Clinical presentation, etiology, and outcome of infective endocarditis in the 21st century: The international collaboration on endocarditis prospective cohort study. *Arch Intern Med*. 2009; 169(5):463-73.
3. Vieira MLC, Schmidt MLR, Resende MVCd, Janior A. Multiple embolism in a female patient with infective endocarditis: Low back pain and hematuria as the initial clinical manifestations. *Arq Bras Cardiol*. 2002; 78(6):595-7.
4. Fedeli U, Schievano E, Buonfrate D, Pellizzer G, Spolaore P. Increasing incidence and mortality of infective endocarditis: A population-based study through a record-linkage system. *BMC Infect Dis*. 2011; 11(1):48.
5. Sonnevile R, Mirabel M, Hajage D, Tubach F, Vignon PH, Perez P, et al. Neurologic complications and outcomes of infective endocarditis in critically ill patients: the ENDOcardite en REAnimation prospective multicenter study. *Crit Care Med*. 2011; 39(6):1474-1481.
6. Snygg-Martin U, Gustafsson L, Rosengren L, Alsio A, Ackerholm P, Andersson R, et al. Cerebrovascular complications in patients with left-sided infective endocarditis are common: A prospective study using magnetic resonance imaging and neurochemical brain damage markers. *Clin Infect Dis*. 2008; 47(1):23-30.
7. Yanagihara C, Wada Y, Nishimura Y. Infectious endocarditis associated with subarachnoid hemorrhage, subdural hematoma and multiple brain abscesses. *Int Med*. 2003;42(12):1244-7.
8. Ruttman E, Willeit J, Ulmer H, Chevtchik O, Hallfer D, Poewe W, et al. Neurological outcome of septic cardioembolic stroke after infective endocarditis. *Stroke*. 2006;37(8):2094-9.
9. Kanafani ZA, Mahfouz TH, Kanj SS. Infective endocarditis at a tertiary care centre in Lebanon: Predominance of streptococcal infection. *J Infect*. 2002;45(3):152-9.
10. Khan AA, Smith JDS, Kirkman MA, Robertson FJ, Wong K, Dott C, et al. Angiogram negative subarachnoid haemorrhage: Outcomes and the role of repeat angiography. *Clin Neurol Neurosurg*. 2011;115(8):1470-5.

How to cite this article:Yadegarynia D., Shokouhi Sh., Tehrani Sh., Yazdani A. Neurological Complication of Infective endocarditis misdiagnosing with Multiple Sclerosis: A Case Report. *Infection, Epidemiology and Microbiology*. 2017; 3(3): 104-106.