

SARS CoV-2 Infection in a Neonate in Ghana: A Case Report

ARTICLE INFO

Article Type Cas Report

Authors

Adwoa Pokua Boakye-Yiadom, *FWACP*^{1,2}
Emmanuel Ameyaw, *FWACP*^{1,2*}
Anthony Kwame Enimil, *FWACP*^{1,2}
Charles Kumi Hammond, *FWACP*^{1,2}
Vivian Paintsil, *FWACP*^{1,2}
Akua Afritie Ocran, *MWACP*^{1,2}
Naana Wereko Brobby, *MWACP*^{1,2}

How to cite this article

Pokua Boakye Yiadom A., Amey-Boakye-Yiadom AP., Ameyaw E., Enimil AK., Hammond CK., Paintsil V., Afritie Ocran A., Wereko Brobby N., SARS CoV-2 Infection in a Neonate in Ghana: A Case Rep. *Infection, Epidemiology and Microbiology*. 2021; 7(3): 271-275

¹Department of Child Health, School of Medicine and Dentistry, Kwame Nkrumah University of Science and Technology, Kumasi, Ghana

²Directorate of Child Health, Komfo Anokye Teaching Hospital, P. O. Box 1934, Kumasi, Ghana

* Correspondence

Address: Department of Child Health, School of Medicine and Dentistry, Kwame Nkrumah University of Science and Technology, Kumasi, Ghana. Email: eameyaw@knust.edu.gh

Article History

Received: May 15, 2021

Accepted: June 25, 2021

Published: July 20, 2021

ABSTRACT

Backgrounds: The clinical and socioeconomic effects of COVID-19 are still being felt throughout the world. The disease affects people of all age groups, but it is known to have a milder clinical course in children including neonates. There is paucity of data from Sub-Saharan Africa on neonatal COVID-19 infection, and no such case has been reported in the literature in Ghana.

Case presentation: This study presented a case report of a neonate who was found to be positive for COVID-19 infection after presenting symptoms such as respiratory distress, rhinorrhoea, and cough. This neonate was managed with in-hospital standard protocol for sepsis with a focus on pneumonia.

Conclusion: The national guidelines on COVID-19 management were used for the neonate who was recovered and discharged.

Keywords: COVID-19 infection, Neonates, Pneumonia.

CITATION LINKS

- [1] Stawicki SP, Jeanmonod R, Miller AC, Paladino L, Gaieski DF, Yaffee AQ, et al. The 2019–2020 novel coronavirus (severe acute respiratory syndrome coronavirus 2) pandemic: A joint American college of academic international medicine-world academic council of emergency medicine multidisciplinary COVID-19 working group consensus paper. *J Glob Infect Dis*. 2020;12(2):47–93.
- [2] Sagheb S, Lamsehchi A, Jafary M, Atef-Yekta R, Sadeghi K. Two seriously ill neonates born to mothers with COVID-19 pneumonia- a case report. *Ital J Pediatr*. 2020;46(1):137–43.
- [3] Wang S, Guo L, Chen L, Liu W, Cao Y, Zhang J, et al. A case report of neonatal 2019 coronavirus disease in China. *Clin Infect Dis*. 2020;71(15):853–7.
- [4] Trevisanuto D, Cavallin F, Cavicchiolo ME, Borellini M, Calgaro S, Baraldi E. Coronavirus infection in neonates: A systematic review. *Arch Dis Child Fetal Neonatal Ed*. 2021;106(3):330–5.
- [5] Center for Disease Control and Prevention. Evaluation and management Considerations for neonates at risk for COVID-19.
- [6] Coronavirus: 170 Staff At Komfo Anokye Teaching Hospital Test Positive.
- [7] Dumpa V, Kamity R, Vinci AN, Noyola E, Noor A. Neonatal coronavirus 2019 (COVID-19) infection: A case report and review of literature. *Cureus*. 2020;12(5):1–8.
- [8] Gale G, Quigley MA, Placzek A, Knight M, Ladhani S, Draper ES, et al. Characteristics and outcomes of neonatal SARS-CoV-2 infection in the UK: A prospective national cohort study using active surveillance. *Lancet Child Adolesc Health*. 2021;5(2):113–21.
- [9] Aghdam MK, Jafari N, Eftekhari K. Novel coronavirus in a 15-day-old neonate with clinical signs of sepsis, a case report. *Infect Dis*. 2020;52(6):427–9.
- [10] Hinojosa-Velasco A, Bobadilla-Montes de Oca PV, García-Sosa LE et al. A case report of newborn infant with severe COVID-19 in Mexico: Detection of SARS-CoV-2 in human breast milk and stool. *Int J Infect Dis* 2020;100:21–24
- [11] Duke T. Neonatal pneumonia in developing countries. *Arch Dis Child Fetal Neonatal Ed*. 2005;90(3):F211–9.
- [12] World Health Organization. Breastfeeding and COVID-19. World Health Organization; 2021.
- [13] Standard treatment guideline for novel coronavirus infection. 1st Edition. Yamens press limited, 2020:18–26.
- [14] Criteria for releasing COVID-19 patients from isolation. Accessed 11 May, 2021. Available from: <https://www.who.int/news-room/commentaries/detail/criteria-for-releasing-covid-19-patients-from-isolation>

Introduction

COVID-19 infection is an ongoing pandemic caused by severe acute respiratory syndrome coronavirus 2 (SARS-CoV-2) [1]. It was first reported in December 2019 in Wuhan, China [2]. The World Health Organization (WHO) declared the disease as a public health emergency of international concern in January 2020 and as a pandemic in March 2020. Although newborns have been reported to be infected by the disease, most of them have been found to be asymptomatic with a mild clinical course. Severe neonatal cases are rare [3-5].

Komfo Anokye Teaching Hospital (KATH) is the second largest tertiary hospital located in the Kumasi metropolis of Ashanti region of Ghana, which serves as a referral centre for the middle belt and northern part of the country. As at July 2020, 170 health and allied workers of KATH, including the staff of the neonatal ward, were found to be positive for COVID-19 infection in the hospital [6]. The Child Health Directorate reported 14 positive cases admitted in 2020 and 9 new positive cases admitted from January to February 2021. The neonatal ward admits sick babies from birth to 2 months of age. The neonatal ward is divided into cubicles which could accommodate up to 25 neonates. The choice of cubicle for a patient depends on the severity of illness, gestation, and birth weight. There is a 6-bed neonatal intensive care unit, 11 incubators, and 4 radiant warmers for preterm intensive care.

In neonates, COVID-19 infection is thought to occur primarily through respiratory droplets usually during the postnatal period when babies are exposed to mothers and other caregivers who may have SARS-CoV-2 infection [2, 5, 7-8], although vertical transmission may also occur [2, 4, 9]. The clinical features of neonatal COVID-19 infection include fever, lethargy, poor feeding, vomiting, difficulty in breathing, jaundice, cyanosis, and diar-

rhoea [2, 5, 7-9]. Although there are some case reports [2, 4, 7, 9] and few small-scale studies [8] on neonatal COVID-19 infection, none of which have been reported in Ghana.

Objectives: This study presented a case report of a neonate who was found to be positive for COVID-19 infection with symptoms such as respiratory distress, poor feeding, and cough.

Case Report

A 19-day-old female neonate was admitted to the neonatal unit of KATH due to poor feeding for 3 days, difficulty in breathing, cough, and rhinorrhoea for one day.

She was delivered at term via caesarean section (C/S) at KATH due to previous C/S and fetal macrosomia with gravida 3 para 2, both alive. Birth weight was 4.4 kg, and blood glucose at birth was 4.2 mmol/L. The APGAR scores were 7 and 9 at first and fifth minutes after birth, respectively. However, one hour post-delivery, she became breathless, and thus, she was referred to the neonatal ward of KATH. She was managed for transient tachypnea of the newborn (TTN). Her mother did not have gestational diabetes or any chronic disease during pregnancy. She took only regular antenatal vitamins prescriptions.

On examination, the baby did not have dysmorphic features. Her weight was 4.1 kg. She was afebrile (axillary temperature of 36.2 °C); conscious but irritable; well hydrated; pink at oral mucosa, tongue, palms, and conjunctiva; and normal tone in all limbs. Primitive reflexes were intact. Blood sugar was 3.8 mmol/L. She was breathless with flaring alae nasae, intercostal recessions, and lower chest in drawing. Respiratory rate was 80 cycles per minute and regular. Oxygen saturation was 96% on a minimal FIO₂ of 100% at a flow rate of one litre per minute. On auscultation, air entry was reduced bilaterally with bronchial breath sounds but with

no crackles. She had warm extremities with a heart rate of 168 beats per minute, regular and normal heart sounds, and no murmurs. She was diagnosed with bacterial pneumonia with a differential diagnosis of coronavirus pneumonia.

Investigations revealed haemoglobin of 18.5 g/dL, white cell count of $14.5 \times 10^9/L$, MCV of 95 FL, and platelet count of $368 \times 10^9/L$.

Blood culture report revealed no bacterial growth after 5 days of incubation, Chest X-ray was normal,

Nasopharyngeal swabs for SARS-CoV-2 investigation using real time polymerase chain reaction (RT-PCR) for baby and mother were positive, although the mother was asymptomatic. The father and siblings on contact tracing were found to be negative for COVID-19 using RT-PCR.

The baby was admitted to the isolation unit of the neonatal ward. She was kept nil per os and received oxygen via nasal prongs.

Intravenous 10% dextrose in one-fifth of normal saline was given as maintenance at 150 mL/kg of body weight.

Intravenous cefuroxime and gentamicin were initiated awaiting results of laboratory investigations.

Antibiotics were changed to oral azithromycin after the COVID-19 test was found to be positive.

The baby's clinical condition improved gradually from the third to the fifth day of treatment. She was well and actively breastfeeding and totally weaned off from supplementary oxygen with oxygen saturation between 96 and 99% in room air, and her respiratory rate was 34 cycles per minute and regular with clear chest on auscultations.

On the 6th day of isolation and treatment on the neonatal unit, the baby was clinically well and discharged home. Her mother was advised to continue her isolation at home with baby for two weeks. The mother was asymptomatic throughout the period of

illness of the baby. Telephone consultation was done every three days to ensure that the baby was well, and parents had no concerns.

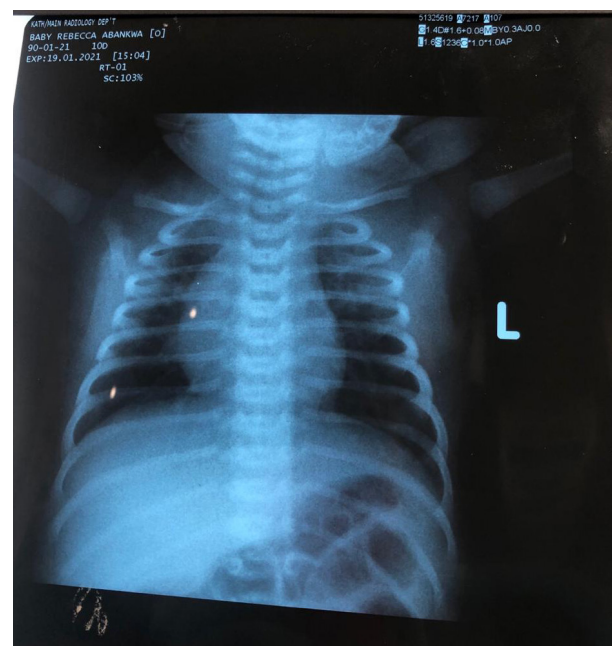


Figure 1) Chest X-ray of the neonate

Discussion

SARS-CoV-2 infection is not common in the neonatal period as compared to the adult population, and usually the prognosis is good [5] as it happened in our patient. The patient was admitted with poor feeding, respiratory distress, rhinorrhea, and cough in the third week of her life, which is the period newborns are usually presented with late onset of COVID-19 infection [5]. However, clinical features of COVID-19 infection in neonates could be varied. Dumpa et al. (2020) [7] reported on a 3 week old neonate with COVID-19 and poor feeding and fever in New York. Kulkarni et al. (2021) [4] also reported fever, poor feeding, and jaundice in a neonate in India. However; Hinojosa-Vasquez et al. (2020) [10] reported on a neonate with severe features such as central cyanosis, dyspnea, and oxygen desaturation. The clinical features as well as examination findings in our patient were also suggestive of neonatal pneumonia [11], although the chest

X-ray findings were not suggestive of which (Figure 1).

The patient was admitted to the same neonatal ward where she was admitted at birth and managed for transient tachypnea of the newborn for 4 days before she was discharged. The patient was presumed to contract COVID-19 infection horizontally through respiratory droplets in the neonatal ward during the previous postnatal admission probably from the mother or other nursing mothers. This is because the neonatal ward is crowded with essentially no observance of COVID-19 safety protocols. The neonatal ward under study still runs at full capacity. Adding mothers to sick neonates makes social distancing practically impossible. Mothers are advised to wear face masks, but they do not strictly adhere to the protocols, and most of them wear their masks wrongly.

Hand sanitizers are readily available on the neonatal wards, but mothers hardly use them. Sinks and taps with running water and soap are readily available, but hand washing is rarely done by mothers. Although the staff adhere strictly to all safety protocols, a number of them are infected with COVID-19 while some of them are asymptomatic^[6], and this could possibly be the cause of the infection transmission to our patient and her mother. There is no conclusive evidence to support transmission of COVID-19 through breast feeding^[10, 12], although it could not be totally ruled out in our patient since the mother's breast milk was not tested for SARS-COV-2.

When the neonate was identified with suspected SARS-COV-2 infection, both the baby and her mother were isolated until the laboratory results of COVID-19 test were ready. This is a standard practice to ensure that other sick newborns on admission are not exposed to possible infected respiratory droplets. The patient was given respiratory

support with oxygen, intravenous fluid, and antibiotics in accordance with management of COVID-19 in newborns^[13]. The full blood count and the chest X-ray were essentially normal contrary to the typical peripheral infiltrates of lower lobes in the lungs commonly observed in adult patients^[13]. Sagheb et al. (2020)^[2] reported on a case of COVID-19 infection in a neonate in Iran with clear chest X-ray. The blood culture was negative after 5 days of incubation, which was supportive of viral infections. After six days of treatment, the patient was well enough to be discharged, evidenced by resolution of symptoms. She was discharged to continue self-isolation at home for 14 days post confirmation of COVID-19 infection as recommended by the World Health Organization^[14].

Conclusion

Doctors and other health workers on neonatal wards should increase their level of suspicion for COVID-19 infection among sick neonates on admission so that they could be screened and tested for early diagnosis and treatment.

Acknowledgements: Authors are grateful to the family for allowing them to publish the data.

Ethical Permissions: All ethical principles were adhered by researchers to protect patient's dignity, right, safety, well-being, and anonymity.

Conflict of interests: None declared by Authors.

Authors' contribution: Conceptualization: APBY and EA; Data curation and formal analysis: AKE and OAA; Investigation: CKH, VP; Methodology and project administration: EA and AKE; Supervision: APBY and EA; Validation: AKE, VP and OAA; Writing of original draft: APBY, EA, NWB and VP; writing, reviewing and editing: EA, CKH, NWB, VP

and OAA.

Funding: None declared by Authors

Consent to participate: Mother signed patient informed consent form.

References

1. Stawicki SP, Jeanmonod R, Miller AC, Paladino L, Gaieski DF, Yaffee AQ, et al. The 2019–2020 novel coronavirus (severe acute respiratory syndrome coronavirus 2) pandemic: A joint American college of academic international medicine-world academic council of emergency medicine multidisciplinary COVID-19 working group consensus paper. *J Glob Infect Dis.* 2020;12(2):47–93.
2. Sagheb S, Lamsehchi A, Jafary M, Atef-Yekta R, Sadeghi K. Two seriously ill neonates born to mothers with COVID-19 pneumonia- a case report. *Ital J Pediatr.* 2020;46(1):137–43.
3. Wang S, Guo L, Chen L, Liu W, Cao Y, Zhang J, et al. A case report of neonatal 2019 coronavirus disease in China. *Clin Infect Dis.* 2020;71(15):853–7.
4. Trevisanuto D, Cavallin F, Cavicchiolo ME, Borellini M, Calgaro S, Baraldi E. Coronavirus infection in neonates: A systematic review. *Arch Dis Child Fetal Neonatal Ed.* 2021;106(3):330-5.
5. Center for Disease Control and Prevention. Evaluation and management Considerations for neonates at risk for COVID-19.
6. Coronavirus: 170 Staff At Komfo Anokye Teaching Hospital Test Positive.
7. Dumpa V, Kamity R, Vinci AN, Noyola E, Noor A. Neonatal coronavirus 2019 (COVID-19) infection: A case report and review of literature. *Cureus.* 2020;12(5):1-8.
8. Gale G, Quigley MA, Placzek A, Knight M, Ladhani S, Draper ES, et al. Characteristics and outcomes of neonatal SARS-CoV-2 infection in the UK: A prospective national cohort study using active surveillance. *Lancet Child Adolesc Health.* 2021;5(2):113–21.
9. Aghdam MK, Jafari N, Eftekhari K. Novel coronavirus in a 15-day-old neonate with clinical signs of sepsis, a case report. *Infect Dis.* 2020;52(6):427–9.
10. Hinojosa-Velasco A, Bobadilla-Montes de Oca PV, García-Sosa LE et al. A case report of newborn infant with severe COVID-19 in Mexico: Detection of SARS-CoV-2 in human breast milk and stool. *Int J Infect Dis* 2020;100:21-24.
11. Duke T. Neonatal pneumonia in developing countries. *Arch Dis Child Fetal Neonatal Ed.* 2005;90(3):F211–9.
12. World Health Organization. Breastfeeding and COVID-19. World Health Organization; 2021.
13. Standard treatment guideline for novel coronavirus infection. 1st Edition. Yamens press limited, 2020:18-26.
14. Criteria for releasing COVID-19 patients from isolation. Accessed 11 May, 2021. Available from: <https://www.who.int/news-room/commentaries/detail/criteria-for-releasing-covid-19-patients-from-isolation>.